AHA/ASA Scientific Statement

Prevention of Stroke in Patients With Silent Cerebrovascular Disease

A Scientific Statement for Healthcare Professionals From the American Heart Association/American Stroke Association

The American Academy of Neurology affirms the value of this statement as an educational tool for neurologists.

Eric E. Smith, MD, MPH, FAHA, Chair; Gustavo Saposnik, MD, MSc, FAHA, Vice Chair; Geert Jan Biessels, MD, PhD; Fergus N. Doubal, PhD, FRCP; Myriam Fornage, MS, PhD, FAHA; Philip B. Gorelick, MD, MPH, FAHA; Steven M. Greenberg, MD, PhD, FAHA; Randall T. Higashida, MD, FAHA; Scott E. Kasner, MD, MS, FAHA; Sudha Seshadri, MD; on behalf of the American Heart Association Stroke Council; Council on Cardiovascular Radiology and Intervention; Council on Functional Genomics and Translational Biology; and Council on Hypertension

Abstract—Two decades of epidemiological research shows that silent cerebrovascular disease is common and is associated with future risk for stroke and dementia. It is the most common incidental finding on brain scans. To summarize evidence on the diagnosis and management of silent cerebrovascular disease to prevent stroke, the Stroke Council of the American Heart Association convened a writing committee to evaluate existing evidence, to discuss clinical considerations, and to offer suggestions for future research on stroke prevention in patients with 3 cardinal manifestations of silent cerebrovascular disease: silent brain infarcts, magnetic resonance imaging white matter hyperintensities of presumed vascular origin, and cerebral microbleeds. The writing committee found strong evidence that silent cerebrovascular disease is a common problem of aging and that silent brain infarcts and white matter hyperintensities are associated with future symptomatic stroke risk independently of other vascular risk factors. In patients with cerebral microbleeds, there was evidence of a modestly increased risk of symptomatic intracranial hemorrhage in patients treated with thrombolysis for acute ischemic stroke but little prospective evidence on the risk of symptomatic hemorrhage in patients on anticoagulation. There were no randomized controlled trials targeted specifically to participants with silent cerebrovascular disease to prevent stroke. Primary stroke prevention is indicated in patients with silent brain infarcts, white matter hyperintensities, or microbleeds. Adoption of standard terms and definitions for silent cerebrovascular disease, as provided by prior American Heart Association/American Stroke Association statements and by a consensus group, may facilitate diagnosis and communication of findings from radiologists to clinicians. **(*Stroke*. 2017;48:e44-e71. DOI: 10.1161/STR.0000000000000116.)**

Key Words: AHA Scientific Statements ■ anticoagulants ■ brain infarction ■ cerebrovascular disorders ■ prevention and control ■ white matter

The American Heart Association makes every effort to avoid any actual or potential conflicts of interest that may arise as a result of an outside relationship or a personal, professional, or business interest of a member of the writing panel. Specifically, all members of the writing group are required to complete and submit a Disclosure Questionnaire showing all such relationships that might be perceived as real or potential conflicts of interest.

This statement was approved by the American Heart Association Science Advisory and Coordinating Committee on August 29, 2016, and the American Heart Association Executive Committee on September 23, 2016. A copy of the document is available at http://professional.heart.org/statements by using either "Search for Guidelines & Statements" or the "Browse by Topic" area. To purchase additional reprints, call 843-216-2533 or e-mail kelle.ramsay@wolterskluwer.com.

The online-only Data Supplement is available with this article at http://stroke.ahajournals.org/lookup/suppl/doi:10.1161/STR.0000000000000116/-/DC1.

The American Heart Association requests that this document be cited as follows: Smith EE, Saposnik G, Biessels GJ, Doubal FN, Fornage M, Gorelick PB, Greenberg SM, Higashida RT, Kasner SE, Seshadri S; on behalf of the American Heart Association Stroke Council; Council on Cardiovascular Radiology and Intervention; Council on Functional Genomics and Translational Biology; and Council on Hypertension. Prevention of stroke in patients with silent cerebrovascular disease: a scientific statement for healthcare professionals from the American Heart Association/American Stroke Association. *Stroke*. 2017;48:e44–e71. doi: 10.1161/STR.0000000000000116.

Expert peer review of AHA Scientific Statements is conducted by the AHA Office of Science Operations. For more on AHA statements and guidelines development, visit http://professional.heart.org/statements. Select the "Guidelines & Statements" drop-down menu, then click "Publication Development."

Neuroimaging signs of silent cerebrovascular disease are highly prevalent in older people. Although many radiological manifestations and secondary consequences are now known, the best-defined manifestations—in terms of radiological definition, prevalence, and clinical associations—are silent brain infarcts, white matter lesions of presumed vascular origin, and microbleeds (Figure 1). Approximately 25% of people >80 years of age have ≥1 silent brain infarcts.[1] The prevalence of silent cerebrovascular disease exceeds, by far, the prevalence of symptomatic stroke. It has been estimated that for every symptomatic stroke, there are ≈10 silent brain infarcts.[2] As a result of this high prevalence, silent cerebrovascular disease is the most commonly encountered incidental finding on brain imaging.[3]

Two decades of research has generated important insights into the prevalence, manifestations, risk factors, and consequences of silent cerebrovascular disease.[4] Silent brain infarcts, also called silent strokes in the literature, are subcortical cavities or cortical areas of atrophy and gliosis that are presumed to be caused by previous infarction.[1] White matter lesions of presumed vascular origin represent areas of demyelination, gliosis, arteriosclerosis, and microinfarction presumed to be caused by ischemia.[4] They may be visible as areas of white matter hyperintensity (WMH) on magnetic resonance (MR) imaging (MRI) or white matter hypodensity on computed tomography (CT). Microbleeds are thought to represent small areas of hemosiderin deposition from previous silent hemorrhages and are visible only on MRI sequences optimized for their detection.[5] A previous statement from the American Heart Association/American Stroke Association (AHA/ASA) on the definition of stroke includes, for the first time, definitions of silent brain infarcts and silent brain hemorrhages as manifestations of cerebrovascular disease.[6]

Although often called silent because they occur in the absence of clinically recognized stroke symptoms, population-based epidemiological studies show that these manifestations of cerebrovascular disease are, in fact, associated with subtler cognitive and motor deficits on standardized testing, cognitive decline, gait impairment, psychiatric disorders, impairments in activities of living, and other adverse health outcomes.[7–9] Furthermore, both silent brain infarcts and WMHs are associated with future incident cognitive decline and stroke.[10–13] Therefore, these lesions are neither silent nor innocuous.

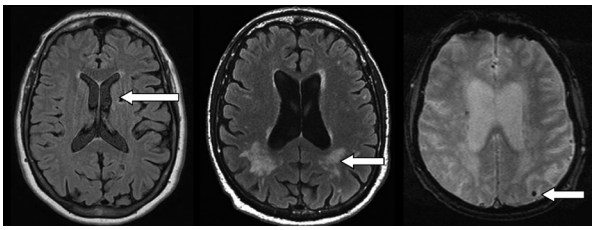

Figure 1. Left, Silent brain infarct (**arrow**) on magnetic resonance imaging (MRI) fluid-attenuated inversion recovery (FLAIR) scan. **Middle,** White matter hyperintensity of presumed vascular origin on MRI FLAIR. **Right,** Microbleed (**arrow**) on MRI T2*-weighted gradient-recalled echo sequence. See the Diagnosis of Silent Cerebrovascular Disease by Neuroimaging section for radiological terms and definitions.

Consequently, some have advocated that the term covert cerebrovascular disease is a more appropriate label than silent disease.[14] A previous AHA/ASA statement on vascular contributions to cognitive impairment and dementia reviewed the relationship between silent cerebrovascular disease and clinically identified cognitive impairment.[15] Salient findings and recommendations in the statement included that a pattern of diffuse, subcortical cerebrovascular pathology, identifiable on neuroimaging, can support a diagnosis of probable or possible vascular cognitive impairment. However, that statement did not offer guidance for stroke prevention.

In this statement, we systematically review the literature on the prevalence of silent cerebrovascular disease and its implications for stroke prevention. Our writing committee identified specific scenarios in which clinical decision making may be influenced by the presence of incidentally detected silent cerebrovascular disease. We conducted focused literature searches to address these clinical questions: (1) How should silent cerebrovascular disease be classified radiologically and reported? (2) What investigations, if any, should be ordered for patients with silent cerebrovascular disease? (3) How should patients with silent brain infarcts or WMHs be managed to prevent symptomatic stroke? (4) What is the safety of medical therapies, including anticoagulation, in patients with cerebral microbleeds (CMBs)? (5) What is the safety of thrombolysis or acute stroke reperfusion therapy in patients with microbleeds? (6) Is there a role for population screening for silent cerebrovascular disease? For each section, we offer suggestions and considerations for clinical practice (summarized in Table 1) and identify areas that require further investigation.

Methods

The writing committee was commissioned in September 2014 to review the literature on the management of silent cerebrovascular disease to reduce the risk of stroke and to improve outcomes from stroke, with the goal of identifying clinical considerations that should drive future research. With guidance from the Stroke Council Scientific Statements Oversight Committee, the writing committee chairs selected commonly encountered clinical scenarios in which there was uncertainty or controversy concerning the implications of silent cerebrovascular disease for patient management. These scenarios were subsequently discussed and finalized with the entire writing committee. Because the frequency of these clinical scenarios depends heavily on the prevalence of silent cerebrovascular disease, the committee chose to summarize existing data on prevalence also. The committee focused on the 3 manifestations of silent cerebrovascular disease that are best studied in the literature: silent brain infarcts, WMHs, and microbleeds. Thus, this statement is not intended to provide a comprehensive overview of all the manifestations of silent cerebrovascular disease, nor is it intended to review aspects related to pathology, pathophysiology, and pathogenesis. For background information, the reader is directed to excellent recent comprehensive reviews[4,16] and to reviews of silent brain infarcts,[1] WMHs,[17] and microbleeds.[18]

In September 2014, the writing committee members were selected by the committee chair and vice chair, with input

Table 1. Summary of Suggestions for Clinical Care of Patients With Silent Cerebrovascular Disease

Diagnosis by neuroimaging
MRI has greater sensitivity than CT for diagnosis of silent cerebrovascular disease.
Minimum MRI acquisition standards are provided in Table 2.
Radiology reports should describe silent cerebrovascular disease according to STRIVE.[16]
WMHs of presumed vascular origin should be reported with the use of a validated visual rating scale such as the Fazekas scale for MRI.[19]
Investigations for patients with silent cerebrovascular disease
Assess common vascular risk factors and assess pulse for atrial fibrillation.
Consider carotid imaging when there is silent brain infarction in the carotid territory.
Consider echocardiography when there is an embolic-appearing pattern of silent infarction.
Consider noninvasive CT or MR angiography when there are large (>1.0 cm) silent hemorrhages.
Prevention of stroke in patients with silent brain infarcts
Take a careful history to determine whether the infarction was symptomatic.
Implement preventive care recommended by AHA/ASA guidelines for primary prevention of ischemic stroke.
The effectiveness of aspirin to prevent stroke has not been studied in this setting.
The clinician should be aware that there is an increased risk for future stroke, and it is reasonable to consider this information when making decisions about anticoagulation for atrial fibrillation, revascularization for carotid stenosis, treatment of hypertension, and initiation of statin therapy. However, the clinician should also be aware that the role of silent brain infarcts in these decisions has not been studied in RCTs.
Prevention of stroke in patients with WMHs of presumed vascular origin
Implement preventive care recommended by AHA/ASA guidelines for primary prevention of ischemic stroke.
It is not clear whether WMH alone, in the absence of other risk factors, is a sufficient reason for aspirin therapy.
The clinician should be aware that there is an increased risk for future stroke, and it is reasonable to consider this information when making decisions about anticoagulation for atrial fibrillation, revascularization for carotid stenosis, treatment of hypertension, and initiation of statin therapy. However, the clinician should also be aware that the role of WMH burden in these decisions has not been studied in RCTs.
Anticoagulation and other therapies in patients with silent microbleeds
It is reasonable to provide anticoagulation therapy to patients with microbleeds when there is an indication (eg, AF).
When anticoagulation is needed, a novel oral anticoagulant is preferred over warfarin.
Percutaneous closure of the left atrial appendage could be considered as an alternative to anticoagulation.
It is reasonable to provide antiplatelet therapy to patients with microbleeds when there is an indication.
MRI screening for microbleeds is not needed before the initiation of antithrombotic therapies.

(*Continued*)

Table 1. Continued

Individuals with silent microbleeds are at increased future risk of both ischemic stroke and ICH.
Implement preventive care recommended by AHA/ASA guidelines for primary prevention of ischemic stroke.
It is reasonable to provide preventive care recommended by AHA/ASA guidelines for prevention of ICH.
Safety of acute ischemic stroke therapy in patients with silent microbleeds
It is reasonable to administer intravenous alteplase to patients with acute ischemic stroke and evidence of microbleeds if it is otherwise indicated.
It is reasonable to perform endovascular thrombectomy in patients with acute ischemic stroke and evidence of microbleeds.
In acute ischemic stroke patients with microbleeds, bypassing intravenous alteplase therapy to proceed directly to endovascular thrombectomy is an unproven strategy.
Population screening
Screening the asymptomatic general population with MRI to detect silent cerebrovascular disease is not justified by current evidence.

AF indicates atrial fibrillation; AHA/ASA, American Heart Association/American Stroke Association; CT, computed tomography; ICH, intracerebral hemorrhage; MR, magnetic resonance; MRI, magnetic resonance imaging; RCT, randomized controlled trial; STRIVE, Standards for Reporting Vascular Changes on Neuroimaging; and WMH, white matter hyperintensity.

from the Stroke Council Scientific Statements Oversight Committee and AHA councils. Committee members were selected on the basis of expert knowledge in this area and experience with guideline development. Care was taken to achieve a balance of early- and later-career investigators, as well as a balance in terms of sex, race, and ethnicity. All committee members were required to declare conflicts of interest.

The first conference call was held in January 2015. During this call, the purpose and topics of the statement were finalized, and literature search strategies were developed. Each of the 8 statement sections was assigned a lead and secondary author, and the chair and vice chair were responsible for drafting the introduction, methods, and concluding sections and for editing all subsections.

For each section, relevant literature was identified through systematic review complemented by hand searching of reference lists and expert knowledge of relevant articles. Literature searches were conducted centrally, with the PubMed engine used to search the Medline database. Key words and medical subject heading terms relevant to silent brain infarcts, WMHs, and microbleeds were used, along with terms specific to section topics of prevalence, diagnosis, stroke prevention, anticoagulation and thrombolysis treatment, and screening (Data Supplement Methods). The section writing lead reviewed abstracts and titles for relevance and abstracted useful information from the full articles; however, detailed evidence tables were not required. Full details of the search strategy are available in the Data Supplement Methods.

The statement was independently peer-reviewed. It was also reviewed internally by AHA Stroke Council leadership and the Stroke Council Scientific Statements Oversight Committee. The writing committee responded in writing to

Table 2. Image Acquisition Standards for Neuroimaging of Small Vessel Disease

Sequence	Purpose	Orientation	Target Slice Thickness, mm/In-Plane Resolution, mm	Comment
T1-weighted	Important for discriminating lacunes from dilated PVS, discriminating gray from white matter, and studying brain atrophy	2D axial, sagittal, or coronal	3–5/1×1	At least 1 sequence acquired in sagittal or coronal plane is helpful in visualizing full extent and orientation
DWI	Most sensitive sequences for acute ischemic lesions; positive up to several weeks after event	2D axial	3–5/2×2	Reduced signal on apparent diffusion coefficient map helps identify recent from old lesions
T2-weighted	Brain structure; differentiate lacunes from WMH and PVS; identify old infarcts	2D axial	3–5/1×1	
FLAIR	Identify WMHs and established cortical or large subcortical infarcts; differentiate white matter lesion from PVS and lacunes	2D axial	3–5/1×1	
T2*-weighted SWI or GRE	Detect hemorrhage, cerebral microbleeds, and siderosis	2D axial	3–5/1×1	Only reliable routine sequences for detection of hemorrhage; SWI is more sensitive than GRE

2D indicates 2-dimensional; DWI, diffusion weighted imaging; FLAIR, fluid-attenuated inversion recovery; GRE, gradient-recalled echo; PVS, perivascular space; SWI, susceptibility-weighted imaging; and WMH, white matter hyperintensity.

Reprinted from Wardlaw et al[16] in *The Lancet Neurology* with permission from Elsevier. Copyright © 2013, Elsevier Ltd.

each comment from the reviewers. Final approval was provided by the AHA Science Advisory and Coordinating Committee.

Diagnosis of Silent Cerebrovascular Disease by Neuroimaging

Silent cerebrovascular disease is typically recognized on brain MRI and CT scans. MRI has greater sensitivity and specificity than CT[16] and can better demonstrate and differentiate small cortical and subcortical infarction, lacunar infarcts, WMHs, perivascular spaces, brain atrophy, and other structural lesions (Figure 1). CMBs are visible on hemorrhage-sensitive MRI sequences but unapparent on CT.

MRI Acquisition

A comprehensive MRI evaluation for silent cerebrovascular diseases should include a minimum of the following sequences: axial diffusion-weighted imaging with both a trace image and an apparent diffusion coefficient map, fluid-attenuated inversion recovery (FLAIR), T2-weighted and T2* susceptibility-weighted imaging (or T2*-weighted gradient-recalled echo if susceptibility-weighted imaging is not available), and T1-weighted imaging. The diffusion-weighted trace image and apparent diffusion coefficient map are important for identifying recent infarcts. Sequence parameters should be consistent with recommendations for neuroimaging from the American College of Radiologists,[20] including that the slice thickness should be ≤5 mm and in-plane resolution should be ≤1×1 mm. For increased sensitivity to small infarcts and microbleeds, slice thickness should ideally be ≤3 mm and slice gaps should be minimized or slices should be acquired with no gaps. Whole-brain coverage in all sequences should be used. Three-dimensional T1-weighted thin-section isotropic sequences can be reformatted to allow coregistration and to quantify brain volume. An MRI field strength of 3.0 T is preferred for higher resolution; however, modern 1.5-T MRI scans are also acceptable.[21] In either magnet, brain coils should always be used. Table 2 outlines the proposed MRI acquisition standards for neuroimaging for clinical care or epidemiological studies.[16]

A number of other techniques are currently under investigation, but their role in clinical practice is still uncertain. Diffusion tensor imaging has been used to assess surrogates of microarchitectural integrity and structural connectivity and to reconstruct white matter tracts in normal- and abnormal-appearing white matter. Other techniques measure perfusion (by arterial spin label or perfusion-weighted MRI), magnetization transfer, blood-brain barrier permeability, vascular reactivity, metabolites, microatheroma in perforating arterioles, and microinfarcts, all of which may be clinically silent but may show lesional abnormalities on high-resolution MRI.[16]

Consensus Terms and Definitions for MRI and CT Manifestations of Silent Cerebrovascular Disease

Most silent cerebrovascular findings on MRI are related to cerebral small vessel disease. The first neuroimaging consensus document for classification of small vessel disease was proposed in 2006 by the US National Institute of Neurological Disorders and Stroke and the Canadian Stroke Network as part of the development of standards for research on vascular cognitive impairment.[22] More recently, a scientific statement from the AHA/ASA incorporated neuroimaging evidence of cerebrovascular disease for vascular cognitive impairment and dementia.[15]

The radiological definitions and terms used to describe silent cerebrovascular disease have varied substantially in research studies and in clinical practice.[16,23,24] STRIVE (Standards for Reporting Vascular Changes on Neuroimaging) was an international collaboration to recommend standards for research and to develop definitions and imaging standards for describing signs of small vessel disease on MRI and CT in the context of aging and neurodegeneration (Table 3).[16] These terms and definitions

Table 3. Glossary of Proposed Terms and Definitions for Neuroimaging Features of Small Vessel Disease

Lesion	Definition
Recent small subcortical infarct	Neuroimaging evidence of recent infarction in the territory of 1 perforating arteriole, with imaging features or clinical symptoms consistent with a lesion occurring in the previous few weeks.
Lacune of presumed vascular origin	A round or ovoid, subcortical, fluid-filled cavity (signal similar to CSF) between 3 and ≈15 mm in diameter, consistent with a previous acute small subcortical infarct or hemorrhage in the territory of 1 perforating arteriole.
WMH (MRI) or hypodensity (CT) of presumed vascular origin	Signal abnormality of variable size in the white matter that shows the following characteristics: hyperintensity on T2-weighted images such as FLAIR or hypodensity on CT, without cavitation (signal different from CSF). Lesions in the subcortical gray matter or brainstem are not included in this category unless explicitly stated. If deep gray matter and brainstem MRI hyperintensities (or CT hypodensities) are also included, the collective term should be MRI subcortical hyperintensities (or CT subcortical hypodensities).
Perivascular space	Fluid-filled spaces that follow the typical course of a vessel as it goes through gray or white matter. The spaces have signal intensity similar to CSF on all sequences. Because they follow the course of penetrating vessels, they appear linear when imaged parallel to the course of the vessel and round or ovoid, with a diameter generally <3 mm, when imaged perpendicular to the course of the vessel.
Microbleed	Small (generally 2–5 mm in diameter but sometimes up to 10 mm) areas of signal void with associated blooming seen on SWI, T2*-weighted MRI, or other sequences that are sensitive to susceptibility effects.
Atrophy	A lower brain volume that is not related to a specific macroscopic focal injury such as trauma or infarction. Thus, infarction is not included in this measure unless explicitly stated.

CMB indicates cerebral microbleed; CSF, cerebrospinal fluid; CT, computed tomography; FLAIR, fluid-attenuated inversion recovery; MRI, magnetic resonance imaging; SWI, susceptibility-weighted imaging; and WMH, white matter hyperintensity.

Reprinted from Wardlaw et al[16] in *The Lancet Neurology* with permission from Elsevier. Copyright © 2013, Elsevier Ltd.

apply to currently recognized manifestations of cerebral small vessel disease, which accounts for the majority (85%–90%) of silent cerebrovascular disease. However, a minority (≈10%–15%) of silent cerebrovascular disease is instead manifest as cortical infarcts or larger (>15 mm) subcortical infarcts related to large artery disease, cardioembolism, or other mechanisms rather than small vessel disease.[25]

Radiological Diagnosis and Reporting of Silent Brain Infarcts, WMHs, and Microbleeds

Silent Brain Infarcts

Most silent brain infarcts (80%–90%) are subcortical. Subcortical chronic infarcts appear as focal, irregularly shaped lesions with T1 hypointensity and T2 hyperintensity, reflecting tissue destruction and cavitation (Figure 2). They usually, but not always, exhibit central hypointensity on the FLAIR sequence, often with an irregular rim of T2 hyperintensity reflecting adjacent gliosis; however, sometimes they appear hyperintense on FLAIR as a result of incomplete suppression of the intracavitary fluid (Figure 3).[26] On CT, they appear as areas of hypodensity with attenuation similar to that of cerebrospinal fluid (Figure 2). They are differentiated from perivascular spaces by size (≥3 mm), shape (ovoid and irregular instead of linear or sausage-shaped), and location. Perivascular spaces are common in the basal ganglia and corona radiata but are rarely found in the pons, medulla, or cerebellum, so lesions in these regions are more likely to represent infarcts.[27] They are differentiated from WMHs by the presence of cavitation, apparent as cerebrospinal fluid–like signal on T1-weighted and T2-weighted images. However, longitudinal studies show that some acute lacunar infarcts do not develop cavitation and therefore will be misclassified as WMHs in their chronic phase.[26,28] Additionally, although the size criterion of ≥3 mm is useful to increase the specificity for infarction as opposed to perivascular space, neuropathological studies frequently identify much smaller infarcts, called microinfarcts, that are unapparent on routine clinical imaging.[29,30] Therefore, MRI is likely to substantially underestimate the burden of infarction in some patients. Small subcortical infarcts that are 3 to 15 mm in axial diameter have also been called lacunar infarcts or lacunar lesions and when attributed to vascular disease may also be called lacunes of presumed vascular origin (Table 2). They are presumed to result from the occlusion of a single small perforating artery caused by lipohyalinosis, microatheroma, or, less commonly, emboli. Large subcortical infarcts that exceed the maximum size typically attributed to lacunes (ie, >15 mm axial diameter) may have more diverse causes, including atherosclerotic large artery disease or embolism.

A minority of silent brain infarcts involve the cerebral cortex (Figure 4). In this case, T2 hyperintensity and T1 hypointensity may be present as a result of gliotic changes, along with atrophic, involutional changes of the cerebral cortex. However, atrophy may be minimal when the cortical infarct is small. Higher-field-strength (3 T) imaging at high spatial resolution (eg, ≤1.5-mm slice thickness), as is sometimes used clinically in dementia protocols, may reveal very small (<3 mm) infarcts in the cortical ribbon that are at the upper size limit of what have been called microinfarcts.[31]

White Matter Hyperintensities

WMH is a descriptive term for areas of increased signal intensity of the cerebral white matter detected on T2-weighted or FLAIR MRI or areas of hypodensity seen on CT (Figure 5). Depending on the MRI acquisition parameters, WMHs may appear isointense on T1-weighted sequences or hypointense, but they should not be as hypointense as cerebrospinal fluid (in which case the lesion should instead be classified as an infarct if presumed to be of vascular origin). Two varieties of WMHs have been described by some investigators on the basis of their location in the brain, periventricular WMHs (immediately contiguous to the ventricular system) and deep WMHs (located in the subcortical

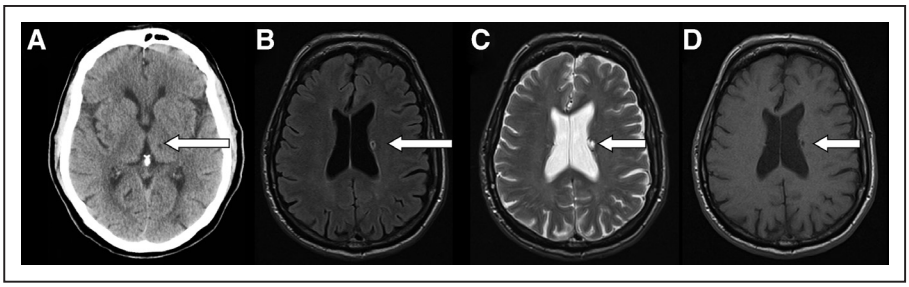

Figure 2. A small (4-mm) subcortical silent brain infarct is visible as a hypodensity in the left thalamus on computed tomography (**A**). On magnetic resonance imaging (different patient), a 4-mm subcortical silent brain infarct (**arrow**) is visible on fluid-attenuated inversion recovery (FLAIR; **B**), T2-weighted (**C**), and T1-weighted (**D**) sequences, illustrating typical imaging features of small subcortical (lacunar) infarction. On FLAIR, the lesion exhibits central hypointensity with a surround rim of hyperintensity, reflecting gliosis. (This peri-infarct hyperintensity may sometimes be absent.) The infarct exhibits hyperintensity on T2-weighted and hypointensity on T1-weighted images, similar to the signal from cerebrospinal fluid, indicating central cavitation.

regions and not contiguous with the ventricles), whereas others aver that subcortical WMHs appear as the total volume of WMH increases above a threshold.[32]

WMH reporting may be the most variable of all the manifestations of silent cerebrovascular disease. Many synonyms for WMH such as leukoaraiosis, white matter changes, and small vessel ischemic disease have entered the literature. WMHs become ubiquitous with advanced age; therefore, clinical reports may neglect to mention their presence when the amount of WMH is expected for age, although there is no clear scientific evidence for a threshold below which WMH can be considered entirely benign. Furthermore, there is no uniform approach to describing the extent of WMH. However, there are opportunities to make reporting more uniform. The STRIVE group recommends adoption of the term T2 WMHs, or CT white matter hypodensity, of presumed vascular origin as a consensus term to confer the diagnostic impression that the white matter changes are probably related to arteriosclerotic microvascular diseases associated with aging and vascular risk factors and are not attributable to other specific white matter diseases, including demyelinating disease, leukodystrophy, and other nonvascular causes.[33,34] Several rapid, easy-to-use visual rating scales have been developed and validated against quantitative volumetric assessments, which would allow standardized reporting of WMH extent across a wide range of WMH.[35,36] Probably the quickest to apply and among the best validated is the Fazekas scale (Figure 6) (see also the White Matter Hyperintensity section in Prevalence of Silent Brain Infarcts, WMHs, and Microbleeds).[19]

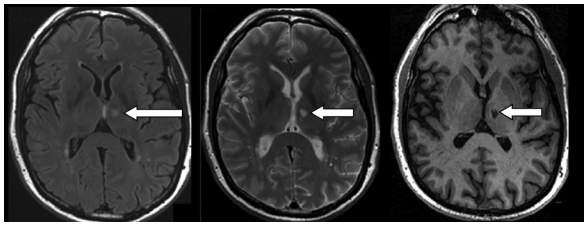

Figure 3. There is a 5-mm left thalamic hyperintensity (**arrow**) on the fluid-attenuated inversion recovery (FLAIR) sequence (**left**) with clear evidence of cavitation based on cerebrospinal fluid–like hyperintensity on T2-weighted (**middle**) and hypointensity on T1-weighted (**right**) images. This lesion should be classified as a brain infarct. Small infarcts can sometimes appear hyperintense on FLAIR because of incomplete suppression of the intracavitary fluid. Modified from Moreau et al.[26] Copyright © 2012, American Heart Association, Inc.

Microbleeds

Microbleeds appear as small, round, 5- to 10-mm areas of signal loss on MRI susceptibility-weighted sequences (Figure 1). They exhibit a blooming effect; that is, the diameter of the signal loss on the susceptibility-weighted sequence exceeds the actual size of the lesion. The sensitivity for their detection can vary up to 2- to 3-fold, depending on the MRI protocol. Longer echo time, higher field strength, higher spatial resolution, and postprocessing techniques can increase the sensitivity.[5] An earlier review provides diagnostic criteria and information on acquisition protocols.[5] There are potential mimics to avoid. Calcium deposits and vessels seen in cross section can have a similar appearance.

Suggestions and Considerations for Clinical Practice

MRI is preferred to CT because of its greater sensitivity for silent cerebrovascular disease and because only MRI can detect chronic microbleeds. We suggest using the minimum MRI acquisition standards in Table 2 for clinical scenarios in which silent cerebrovascular findings are commonly encountered, including when scanning patients with symptomatic stroke or cognitive impairment. Because silent brain infarcts, WMHs, and microbleeds have prognostic value for future clinical events such as symptomatic stroke and dementia, they should be reported when seen on neuroimaging. To reduce variation in reporting terminology, we suggest adoption of the STRIVE standard terms and definitions for clinical reporting of manifestations of cerebral small vessel disease. Using standard terms and definitions should improve communication between radiologists and ordering clinicians. Because WMH increases with advanced age, neuroradiology reports should include a description of the severity of the WMH and its presence. Ideally, WMH severity should be reported with a standardized validated visual rating scale such as the Fazekas scale (Figure 6).

Areas for Further Investigation

MRI exhibits superior contrast to CT for identifying tissue lesions, but more research is needed to quantify the impact

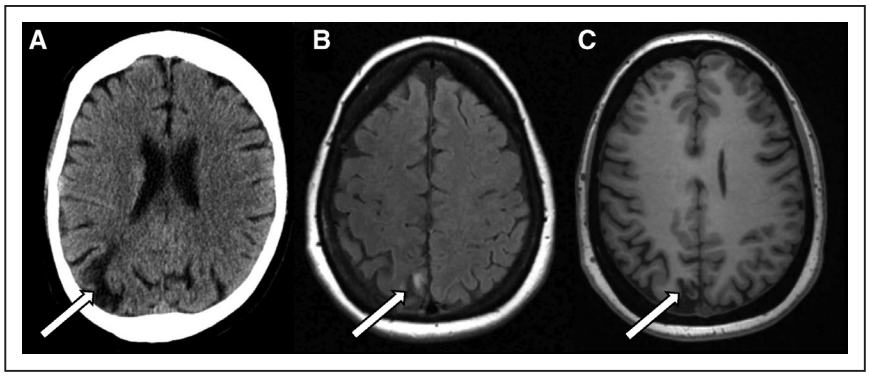

Figure 4. Cortical silent brain infarct. On computed tomography (**A**), a silent cortical infarct is visible in the right parietal lobe (**arrow**). On magnetic resonance imaging (different patient), a silent cortical infarct (**arrow**) is visible as a small region of T2 hyperintensity on the fluid-attenuated inversion recovery image (**B**) in the right parietal cortex and adjacent subcortical white matter. On T1-weighted inversion-recovery spoiled gradient-recalled echo imaging (**C**), the infarct appears hypointense, interrupting the cortical ribbon.

of this improved contrast on the sensitivity, specificity, and reliability for identifying silent brain infarcts and WMHs. This information will be needed to better justify MRI use in practice settings where access to MRI is more limited than access to CT.

Except for microbleeds, there has been very little work on how MRI scanner field strength, scan resolution, and scan parameters affect the sensitivity and specificity for the detection of silent cerebrovascular disease. Future studies should examine the sensitivity, specificity, and reliability for detecting silent brain infarcts and for accurately assessing WMH volume using patient volunteers. The development of appropriate phantoms could help in assessing scanner-related variance.

Generally, moderate to good reliability is reported for assessments of silent brain infarcts, microbleeds, and WMHs.[36] However, these studies report reliability from experienced research groups with a limited number of raters and may overestimate the reliability of reporting that could be expected in routine clinical practice. More research is needed to better understand the sensitivity, specificity, and reliability of reporting findings of silent cerebrovascular disease in clinical practice to identify areas where improvement in reporting is needed.

Investigational MRI techniques may improve the diagnosis of silent cerebrovascular disease in the future. Of particular interest would be techniques that help inform the clinician as to whether the incidentally detected cerebrovascular disease is likely to be associated with subclinical, but real, impairments in cognition, mood, or gait, as well as techniques that improve the detection of small lesions such as microinfarcts and microbleeds. Such techniques could include assessments of perfusion, vascular reactivity, brain white matter connectivity, atrophy, and others.[16]

Prevalence of Silent Brain Infarcts, WMHs, and Microbleeds

We screened >800 studies but included only population-based and case-control studies with >150 subjects, basing our prevalence estimates largely on the community-based data and alluding briefly to data from case-control studies in settings that might be frequently encountered such as an acute stroke setting. Furthermore, we chose to include only MRI studies because the sensitivity of CT scans for the various markers of vascular brain injury is lower. We have focused on 1- to 3-T MRI scans because these are the field strengths that have been widely used to date in population-based studies. We have used the author-defined criteria for silent brain infarction, WMH, and CMB because most of these articles were published before recent harmonization attempts.[16] For estimates of silent brain infarct prevalence, we have included all studies with T1- and T2-weighted imaging; for WMH prevalence studies, either T2-weighted or T2-FLAIR sequences; and for

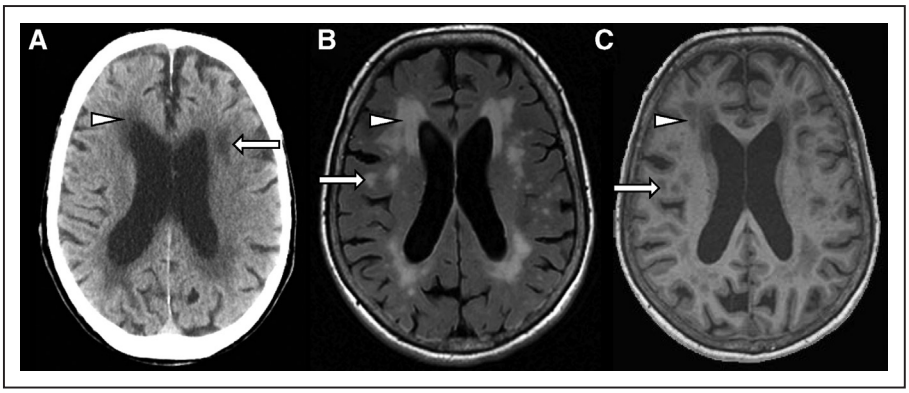

Figure 5. White matter lesions of presumed vascular origin. Extensive periventricular (**arrowhead**) and subcortical (**arrow**) white matter signal abnormalities are seen on computed tomography (CT; **A**) and magnetic resonance imaging (MRI; **B** and **C**). On CT (**A**), the abnormalities appear as white matter hypodensities. On MRI, the abnormalities appear as white matter hyperintensity (WMH) on T2-weighted sequences, including fluid-attenuated inversion recovery (**B**). On T1-weighted inversion-recovery spoiled gradient-recalled echo (**C**), some of the WMH appears mildly to moderately hypointense but without the very hypointense cerebrospinal fluid–like signal indicative of cavitation.

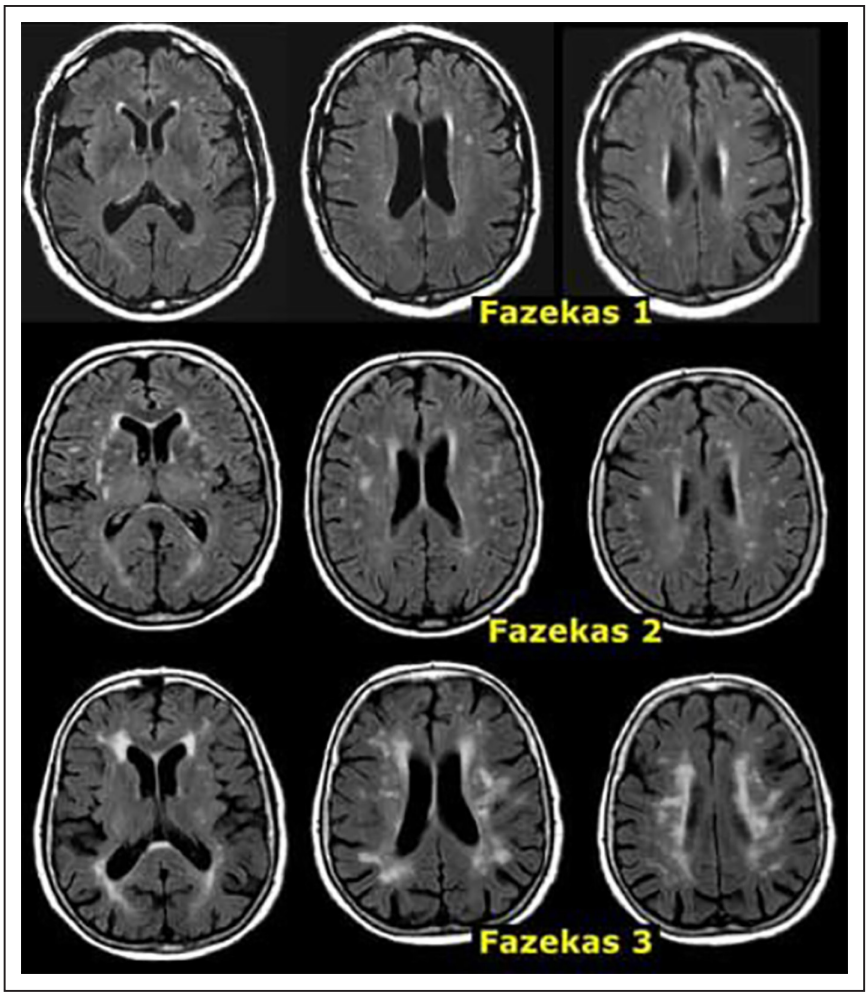

Figure 6. Fazekas visual rating scale for magnetic resonance imaging white matter hyperintensities (WMHs). Periventricular WMH is graded as follows: 0=absence, 1=caps or pencil-thin lining, 2=smooth halo, and 3=irregular periventricular WMH extending into the deep white matter. Separately, deep (subcortical) WMH is graded as follows: 0=absence, 1=punctuate foci, 2=beginning confluence of foci, and 3=large confluent areas. Reprinted from Fazekas et al[19] with permission from the *American Journal of Roentgenology*. Copyright © 1987, American Roentgen Ray Society.

studies of microbleeds, T2*-weighted gradient-recalled echo or susceptibility-weighted imaging.[16]

Silent Brain Infarcts

In population studies, >90% of silent brain infarcts correspond to lacunar infarcts, defined as small subcortical infarcts of 3 to 15 mm, whereas the remaining 10% correspond to larger subcortical infarcts or cortical infarcts.[25] Population-based studies in whites, blacks, and Japanese have reported an overall silent brain infarction prevalence of 8% to 31%,[37–41] with an incidence of 0.3%/y to 3%/y that progressively increases with age.[42–44] In a Framingham study sample 62±9 years of age, the prevalence of silent brain infarction was 10.7%, with 84% having a single infarct.[45]

Silent brain infarcts are more prevalent among patients with cardiovascular disease, stroke, and dementia. Risk factors for silent brain infarcts have been systematically reviewed[1,46] and include advanced age, hypertension, diabetes mellitus, and smoking. One population-based study in a multiethnic cohort also found that men and younger blacks were at increased risk for silent brain infarction.[47]

White Matter Hyperintensity

WMH prevalence and volume are partly genetically determined[48–50] but increase exponentially with age, and the prevalence is greater in individuals with higher levels of and longer exposure to various vascular risk factors, notably hypertension and diabetes mellitus.[51,52] WMHs are likely more common in individuals with stroke, dementia, migraine,[53,54] or late-life depression[55] but not in younger adults with bipolar disease or schizophrenia.[56] In community-based samples, WMH prevalence was low before 55 years of age[57] but increased sharply with age thereafter, from 11% to 21% in the subjects 64 years of age on average to 94% in individuals 82 years of age on average.[8,25,58–60] Whereas most studies have been in whites living in industrialized nations, the prevalence of WMHs in rural Ecuador and in blacks and Hispanics in Northern Manhattan was comparable.[61,62] However, another study suggests that blacks may be at higher risk for more severe WMHs than Americans of European descent.[63] Early studies used a variety of semiquantitative visual rating scales with limited agreement,[8,19,60,64,65] and they reported a prevalence of moderate to severe WMH of ≈22%.[66] In some studies of older adults that additionally categorized WMH by location, a prevalence of 20% to 67% for deep and subcortical WMHs and from 15% to 94% for periventricular WMHs has been noted.[67,68] Currently, automated methods for assessment of WMH volumes are considered the gold standard for research purposes.[69] An entity of large or extensive WMHs has been described as a WMH volume >1 or 1.5 SD above the age- and sex-specific mean; by definition, the prevalence of this condition is 12% to 17%.[70,71]

MRI Fazekas White Matter Hyperintensity Scale Score

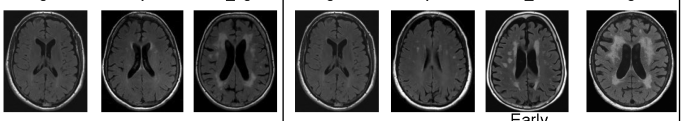

		Periventricular			Subcortical			
		0	1	2-3	0	1	2	3
Age	N	None	Caps/lining	Halo	None	Punctate	Early Confluence	Confluent
<55	440	72%	28%	0%	52%	45%	3%	0%
55-64	644	51%	47%	2%	27%	66%	5%	2%
65-74	563	34%	57%	9%	12%	60%	22%	6%
≥75	149	6%	74%	19%	3%	44%	30%	23%

Figure 7. Distribution of magnetic resonance imaging (MRI) white matter hyperintensity by age category in the general population, measured with the Fazekas scale (Figure 6). Data were derived from 2 population-based studies of aging.[74,75]

In specific settings such as in patients who have suffered an acute stroke, semiautomated methods that mask the acutely infarcted areas to assess WMH only in noninfarcted brain are used that correlate well with methods used in stroke-free population samples[72]; individuals with stroke have more prevalent WMHs (19.5% had confluent WMHs versus 7.5% of normal) and larger WMH volumes.[73]

Estimates of WMH volume are dependent on the MRI sequences and the WMH measurement methods used; thus, it is uncertain whether they can be directly compared across studies. Figure 7 provides estimates of the frequency of different WMH grades, measured on FLAIR with the Fazekas visual rating scale (Figure 6), for age categories from <55 to >75 years of age based on the findings of 2 population-based studies.[74,75] Unfortunately, similar normative data are not available for CT.

The most consistently identified risk factors for WMH are advanced age and hypertension.[8,63,70,76]

Cerebral Microbleeds

CMBs were found in up to 5% to 21% of the general population,[20,77–84] 30% to 40% of patients with ischemic stroke, and 60% to 68% of patients with primary intracerebral hemorrhage (ICH) with the use of gradient-recalled echo sequences.[85] Microbleeds are strongly associated with age. On a high-sensitivity MR sequence, CMBs were found in 18% of individuals 60 to 69 years of age and in 38% of subjects >80 years of age, whereas using less sensitive gradient-recalled echo sequences, the Framingham and AGES (Age, Gene/Environment Susceptibility) studies noted a prevalence of 9% and 13% at mean ages of 67 and 76 years, respectively.[81,84] Prevalence was similar in a multiethnic cohort, the Washington Heights-Inwood Columbia Aging Project.[86]

Technical and measurement-related factors may influence CMB prevalence rates. Most important, MRI parameters such as longer echo time, smaller interslice gap, and the use of 3-dimensional acquisition, a higher magnetic field, and newer sequences such as susceptibility-weighted imaging can increase the ability to detect microbleeds by 2- to 3-fold.[5,20] Additionally, the reliability of microbleed identification is only moderate, probably because of the presence of mimics such as flow voids, cavernous malformations, hemorrhagic transformation of small infarcts, iron deposition, and scattered calcifications that can be misidentified as microbleeds.[5]

Risk factors for microbleeds have been systematically reviewed[20] and include advanced age and hypertension. Cerebral amyloid angiopathy (CAA) is a risk factor for lobar microbleeds, and a pattern of microbleeds restricted to lobar locations is diagnostic for CAA in specific clinical settings (Table 4, Boston criteria). A mixed pattern of both deep and lobar microbleeds is not uncommon, caused by either arteriosclerosis (resulting from hypertension, aging, and other risk factors) or a combination of arteriosclerosis and CAA.

Suggestions and Considerations for Clinical Practice

Because of the high prevalence of silent cerebrovascular disease, it will be encountered frequently as an incidental finding on brain MRI and CT scans, particularly in older people. Cerebrovascular disease was the most commonly encountered incidental brain finding in the Rotterdam Scan Study and Cardiovascular Health Study, with a prevalence exceeding that of all other incidental findings (eg, meningiomas and arachnoid cysts) combined.[3,89] Implications for clinical care are discussed in subsequent sections of this statement.

Areas for Further Investigation

More prevalence data are needed in younger populations and from non–North American, non-European countries. Normative data on the population prevalence and severity of WMH by age are needed, but to pool data from existing cohorts, a standardized WMH assessment method would need to be selected. These normative data would help clinicians accurately identify patients with excessive WMHs for a given age. Additional population-based, longitudinal studies on CMBs would be valuable, addressing the impact of disease location (eg, deep versus lobar microbleeds) and disease burden on outcomes, including future risk of stroke and cognitive decline.

Investigations for Patients With Silent Cerebrovascular Disease

This section reviews considerations for diagnostic investigations in the commonly encountered clinical scenarios in which ≥1 silent brain infarcts, extensive WMHs for a given age, or ≥1 silent CMBs are incidentally discovered on brain imaging done for unrelated reasons. We focus on

Table 4. Modified Boston Criteria for the Diagnosis of CAA

Definite CAA	Full postmortem examination demonstrating: 1. Lobar, cortical, or corticosubcortical hemorrhage 2. Severe CAA with vasculopathy 3. Absence of other diagnostic lesion
Probable CAA with supporting pathology	Clinical data and pathological tissue (evacuated hematoma or cortical biopsy) demonstrating: 1. Lobar, cortical, or corticosubcortical haemorrhage 2. Some degree of CAA in the specimen 3. Absence of other diagnostic lesion
Probable CAA	Clinical data and MRI or CT demonstrating: 1. Age ≥55 y 2. Either (a) multiple hemorrhages restricted to lobar, cortical, or corticosubcortical regions (cerebellar hemorrhage allowed) or (b) single lobar, cortical, or corticosubcortical hemorrhage and focal or disseminated superficial siderosis 3. Absence of other cause of hemorrhage or superficial siderosis
Possible CAA	Clinical data and MRI or CT demonstrating: 1. Age ≥55 y 2. Either (a) single lobar, cortical, or corticosubcortical hemorrhage or (b) focal or disseminated superficial siderosis 3. Absence of other cause of hemorrhage or superficial siderosis

Hemorrhages may be either hematomas or magnetic resonance imaging–defined microbleeds. The criteria have been pathologically validated to have high specificity and positive predictive value in the setting of lobar intracerebral hemorrhage[87] but have been less validated in the general population without hemorrhagic stroke.[88]

CAA indicates cerebral amyloid angiopathy; CT, computed tomography; and MRI, magnetic resonance imaging.

Modified from Linn et al[87] with permission of the publisher. Copyright © 2010, by AAN Enterprises, Inc.

investigations to identify mechanisms of cerebrovascular disease and risk factors that would inform primary prevention of symptomatic stroke. A full discussion of the differential diagnosis of nonvascular causes of cystic brain lesions or white matter signal abnormalities is outside the scope of this statement. However, the reader should be aware that nonvascular causes of such lesions exist. For example, adult-onset leukoencephalopathies or demyelinating disease can also cause WMHs on MRI.[33,34] Here, we focus on circumstances in which the radiology and medical history are considered sufficient to exclude nonvascular causes and are instead consistent with incidental silent cerebrovascular disease. Additionally, we do not provide suggestions for the assessment of patients with symptomatic cerebrovascular disease; instead, the reader should refer to AHA guidelines for secondary prevention of stroke.[90] Finally, we do not provide detailed discussions of workup for rare genetic causes of cerebral small vessel disease such as cerebral autosomal dominant arteriopathy with subcortical ischemic leukoencephalopathy (CADASIL), which are usually symptomatic on presentation but may be detected in asymptomatic mutation carriers before disease onset. However, we provide suggestions for when rare genetic causes could be suspected.

Investigations for Patients With Silent Brain Infarcts

The diagnostic approach to clinically apparent, symptomatic ischemic stroke is typically 2-pronged: identifying common vascular risk factors and determining the underlying mechanistic cause of the stroke. Because both silent brain infarction and ischemic stroke are presumed to share the same pathology, namely cerebral infarction, the diagnostic approach to silent infarction arguably ought to be the same. However, evidence supporting this approach is sparse.

The evaluation of typical vascular risk factors, including hypertension, diabetes mellitus, dyslipidemia, cigarette smoking, and physical inactivity, is relatively straightforward and is discussed in detail in existing guidelines for both primary and secondary prevention of stroke.[91]

The diagnosis of ischemic stroke origin is a major component of early evaluation because it has potential implications for treatment. The origin is often classified as 1 of the following 5 mechanisms: cardioembolism, large vessel atherothromboembolism, small vessel occlusive disease, other determined cause, or cryptogenic (idiopathic) causes.[92,93] Mechanistically, these same categories seem reasonably applied to silent infarction, but the reliability of this approach has not been studied. Most silent infarcts (80%–90%) are subcortical and <1.5 cm in maximal diameter and would therefore most likely be classified as small vessel occlusive disease or lacunar infarction. Only a minority (10%–20%) are cortical or large infarcts that are more likely to arise from a proximal source of embolism from the heart or a proximal larger artery such as the carotid artery.[25] However, the categories of cardioembolism and large-vessel disease are likely the major areas for which specific guidelines are needed in relation to silent infarction because of the strong relationships between diagnostic risk stratification and treatment decisions. Existing AHA/ASA guidelines for early management of symptomatic ischemic stroke recommend cardiac rhythm monitoring in all patients, as well as noninvasive vascular imaging of the cervical vessels and intracranial vessels (when knowledge of intracranial steno-occlusive disease would alter management) in all patients with ischemic stroke or transient ischemic attack (TIA),[94] and by logical extension may also pertain to patients with clinically unrecognized infarction.

The most common cause of cardioembolism is atrial fibrillation (AF). The risk of stroke in patients with AF can be estimated with the $CHADS_2$-VASC scheme, which incorporates congestive heart failure, hypertension, age, diabetes mellitus, prior stroke or TIA, female sex, and vascular disease (including peripheral artery disease, myocardial infarction, or aortic plaque) into a composite score.[95] A score of 0 is considered low risk; a score of 1 is considered moderate risk; and scores of ≥2 are considered high risk. A prior stroke or TIA alone earns 2 points and in itself identifies a patient at high risk. The process that was used to develop and validate this scoring system did not account for silent infarction. However, those studies also did not attempt to characterize prior stroke as specifically attributable to AF or another cause. Furthermore,

history of prior stroke or TIA was not adjudicated and might have included radiographic evidence of prior stroke. Notably, silent infarction is found in about a quarter of patients with AF who have no history of stroke.[96]

From a pathophysiological perspective, any evidence of prior infarction in a patient with AF would seem to correlate with the propensity to form emboli. Observational studies have not been able to confirm or refute this idea, with some suggesting a greater risk of subsequent stroke among those with silent infarction compared with those without[97] and others showing no difference.[98] These studies have not attempted to define silent infarctions as embolic in origin on the basis of their radiographic appearance. However, an analysis of patients with recent cryptogenic ischemic stroke found that radiographic evidence of prior cortical or cerebellar (presumably embolic-appearing) infarction was associated with a 3-fold increase in the likelihood of finding AF with 28 days of continuous cardiac monitoring.[99] This suggests that patients with such patterns of silent infarction may benefit from monitoring. The AHA/ASA guideline on the primary prevention of stroke states that "active screening for AF in the primary care setting in patients >65 years of age by pulse assessment followed by ECG as indicated can be useful."[91] For patients found to have silent brain infarction, a similar strategy seems appropriate at a minimum, regardless of age. The AHA/ASA guidelines for secondary prevention recommend that "for patients who have experienced an acute ischemic stroke or TIA with no other apparent cause, prolonged rhythm monitoring (≈30 days) for AF is reasonable within 6 months of the index event." For patients with silent infarction, the timing of the "event" is unknown, and the value of extensive rhythm monitoring is not determined. The role of echocardiography is undefined in guidelines for recent symptomatic stroke (although it is often performed in this setting), and its utility in silent stroke has not been investigated.

Stenosis of the internal carotid artery is also a well-established cause of cerebral infarction, with a high risk of subsequent stroke (≈10%/y–15%/y) among patients who have recently been symptomatic with a TIA or ischemic stroke and a much lower risk (≈2%/y) among those who are asymptomatic. The AHA/ASA guidelines for secondary prevention recommend carotid revascularization for eligible patients with symptomatic internal carotid artery stenosis of 50% to 99% and recent TIA or ischemic stroke within 6 months[90]; however, for patients with silent brain infarction, the timing of the infarction is unknown. Silent infarctions are found in about a quarter of patients with asymptomatic carotid stenosis but do not consistently appear to be more common on the side of the carotid stenosis.[100–103] As with AF, data relating silent infarction to subsequent risk are limited but suggest greater risk of subsequent stroke and mortality among those with preoperative silent infarction. A systematic review and meta-analysis found 2 studies that showed that a nonlacunar pattern of cortical and subcortical silent CT infarctions ipsilateral to the carotid stenosis was associated with future stroke risk (pooled odds ratio [OR], 4.6; 95% confidence interval [CI], 3.0–7.2), but there were no prospective MRI studies linking silent infarction and stroke risk in this setting.[103] This study[103] suggests that the presence of nonlacunar silent infarction is associated with a risk of subsequent stroke about halfway between that of symptomatic and of asymptomatic stenosis (as reported in prior studies without evaluation for silent infarction) and warrants diagnosis and consideration of intervention.

Rarely, the clinician may identify a patient with multiple lacunes and extensive WMHs who is relatively young and without a severe burden of conventional vascular risk factors. In such cases, a monogenic disorder such as CADASIL may be the cause. A family history of early-onset stroke, dementia, or migraine is usually present, although some disorders are autosomal recessive (eg, cerebral autosomal recessive arteriopathy with subcortical infarcts and leukoencephalopathy) and family history will be lacking in cases of spontaneous de novo mutations, which have been described. Monogenic causes of cerebral small vessel disease have been reviewed elsewhere.[104]

Suggestions and Considerations for Investigations in Patients With Silent Brain Infarction

We suggest that it is reasonable for all patients with silent brain infarct infarction to have an assessment of common vascular risk factors, including hypertension, diabetes mellitus, hyperlipidemia, smoking, and physical inactivity, as well as active screening for AF by pulse assessment followed by ECG as indicated. This suggestion is consistent with AHA guidelines for the primary prevention of stroke. For patients with an embolic-appearing pattern of infarction, that is, single or multiple cortical infarcts or large, nonlacunar subcortical infarcts, prolonged rhythm monitoring for AF might be considered. However, evidence is lacking on whether silent brain infarction can be considered equivalent to symptomatic stroke for risk stratification for anticoagulant treatment for AF (see also the Prevention of Symptomatic Stroke in Patients With Silent Brain Infarcts section). The role of echocardiography to identify cardiac sources for embolism has not been defined but could be considered when there is an embolic-appearing pattern of silent brain infarction. Noninvasive carotid imaging may be considered to determine the presence or absence of carotid stenosis in patients with silent brain infarction in the carotid perfusion territory because these patients appear to have an intermediate risk for subsequent brain infarction (between the risk for recently symptomatic [<6 month] and asymptomatic carotid artery stenosis) and therefore could be candidates for carotid intervention, depending on the perioperative risk and patient preferences.

Routine genetic testing for monogenic causes of cerebral small vessel disease is not warranted because they are rare. Genetic testing should be considered only when lacunes are present in a young patient with extensive WMHs in the absence of sufficient conventional vascular risk factors.[105] The presence of migraine, cognitive impairment, and a positive family history are additional features of CADASIL, the commonest monogenic disorder that causes cerebral small vessel disease.[106] CADASIL can be diagnosed on the basis of testing for mutations in the *NOTCH3* gene.[106] For patients with a suspected genetic disorder, referral to a specialist would also be reasonable.

Investigations for Patients With WMHs of Presumed Vascular Origin

WMHs of presumed vascular origin become extremely common with aging, being found to some extent in >90% of individuals ≥70 years of age. Therefore, finding small

scattered WMHs in middle-aged and older people is a frequent, expected finding that does not require additional investigation. However, WMHs that are excessive for age are associated with increased future risk for stroke. Therefore, assessment of vascular risk factors for the primary prevention of stroke and cardiovascular disease is warranted in patients with extensive WMHs. Currently, identifying such patients with extensive WMHs relies on clinical judgment because there has been no consensus on WMH rating methods and, as a result, there are no published, widely accepted normative data for comparison. The presence of confluent or beginning confluent WMHs, corresponding to a Fazekas score of 2 or 3 in the periventricular or subcortical white matter (Figure 6), has sometimes been used as an operational definition of extensive WMH in research studies.

In contrast to silent brain infarcts, less is known about the pathophysiology of WMH. Ischemia, infarction, inflammation, increased vascular permeability, and venous insufficiency have all been proposed as causes of WMHs. It is possible that WMHs may not result from a single pathophysiological pathway but rather may be the common result of a number of pathophysiological disturbances. Furthermore, WMHs have a high heritable component, although the genetic basis for this heritability is not well understood. WMHs are associated with cerebral small vessel diseases, although AF has also been identified as a risk factor in epidemiological studies.[107] WMHs are only weakly associated with subclinical measures of atherosclerotic carotid disease[26,108] and are not more common on the side of the carotid stenosis in patients with symptomatic carotid disease.[109] Extensive, confluent WMHs are also a feature of the rare genetic disorder CADASIL.[106] The presence of WMHs in the anterior temporal white matter or external capsule is typical for CADASIL as indicated by case-control studies,[106] but the positive predictive value of this pattern of WMH has not been tested in population-based studies and may be low in that setting.

Suggestions and Considerations for Investigations in Patients With WMHs of Presumed Vascular Origin

In patients with excessive WMHs for age, including patients with beginning confluent or confluent WMHs (periventricular or subcortical Fazekas score of 2 or 3), we suggest assessment of common vascular risk factors, including hypertension, diabetes mellitus, hyperlipidemia, smoking, and physical inactivity. We also suggest active screening for AF by pulse assessment followed by an ECG as indicated. Investigations for proximal sources of embolism, including carotid imaging and echocardiography, are probably not needed. Routine genetic testing is not indicated and should be reserved for exceptional cases in which the patient is relatively young, other features of CADASIL or other monogenic disorders are present, the WMH is large and confluent, and the burden of WMH is not well accounted for by conventional vascular risk factors.

Investigations for Patients With Silent CMBs

Microbleeds are most commonly associated with hypertensive arteriopathy or CAA. Less common causes include infective endocarditis, multiple cavernous malformations, coagulopathies, and head trauma, which can generally be identified on the basis of the clinical history. Larger silent hemorrhages (>1.0 cm) are less common than microbleeds and probably have a range of causes similar to symptomatic ICH.

Microbleeds have different risk factors, depending on their location. Microbleeds may be subdivided into those occurring in deep brain locations (the basal ganglia and brainstem) and those occurring in lobar brain locations (within the cerebral cortex or subcortical white matter). In 2 population-based studies that looked separately at risk factors for microbleeds in the 2 locations, lobar microbleeds were associated with the presence of the apolipoprotein E (*APOE*) ε4 allele, whereas deep microbleeds were associated with hypertension, smoking, and brain infarcts.[84,110] These findings suggest that CAA, a hypertension-independent small vessel disease that is more common in *APOE* ε4 allele carriers, is a common cause of lobar microbleeds in the general population. The Boston criteria for diagnosis of CAA have been validated pathologically in the context of a history of lobar ICH (Table 4).[111] In patients with hemorrhages restricted to lobar brain locations only, the Boston criteria can be used to diagnose probable or possible CAA, depending on whether multiple lobar hemorrhages or a single lobar hemorrhage is present. A modified version of the criteria incorporates superficial siderosis as a hemorrhage equivalent.[87] However, there is limited validation of the original or modified Boston criteria in the general population.[88] Patients who have a combination of lobar and nonlobar (deep) hemorrhages may have both CAA and arteriosclerosis (caused by aging, hypertension, and other vascular risk factors) as the underlying vascular pathology, although long-standing hypertension can be sufficient to cause microbleeds in all territories.

Suggestions and Considerations for Investigations in Patients With Silent CMBs

In patients with silent microbleeds, we suggest that common risk factors for ICH, particularly hypertension, should be assessed. CT angiography, CT venography, contrast-enhanced CT, contrast-enhanced MRI, MR angiography, and MR venography can be useful to evaluate large (ie, >1.0 cm in diameter) silent hemorrhages for underlying structural lesions, including vascular malformations and tumors, when there is clinical or radiological suspicion. For silent hemorrhages or microbleeds not attributable to secondary causes such as vascular malformations, the modified Boston criteria (Table 4) are probably useful to classify the likelihood of underlying CAA pathology. *APOE* testing is not recommended for patients with ICH because it does not accurately identify patients with CAA[112]; therefore, we do not suggest testing patients with microbleeds either.

Areas for Further Investigation

Research into the causes and pathophysiology of cerebral small vessel disease may yield insights that lead to new diagnostic testing strategies. Of the cardinal manifestations of silent brain cerebrovascular disease reviewed in this statement, the pathophysiology of WMH is probably the least well understood. More research is needed on the diagnostic yield (eg, sensitivity and specificity) of investigations for causes of silent cerebrovascular disease because epidemiological

Table 5. Risk for Future Stroke in Individuals With Silent Brain Infarcts

Study	Setting	Size, n/Mean Age, y	With Silent Brain Infarcts, %	Incident Stroke Events, n	Event Rate in Individuals With Silent Brain Infarcts, %/y	Event Rate in Individuals Without Silent Brain Infarcts, %/y	Adjusted HR (95% CI)
Cardiovascular Health Study[13]	Population-based	3324/74	27.8	159	1.87	0.95	1.5 (1.1–2.1)
Rotterdam Scan Study[10]	Population-based	1077/72	21	57	2.9	0.58	3.3 (1.8–5.9)
Atherosclerosis Risk in Communities Study[108]	Population-based	1884/62	11.7	157	1.6	0.4	2.5 (1.7–3.8)
Framingham study[12]	Population-based	2229/62	11	32	0.5	0.16	2.8 (1.3–6.0)

All HRs were adjusted for age, sex, and vascular risk factors (including hypertension).
CI indicates confidence interval; and HR, hazard ratio.

studies have focused on relative risks. For example, there is limited information on how frequently one would identify clinically important risk factors such as AF or hypertension among patients with silent brain infarcts, WMHs, or microbleeds. At the present time, there is essentially no information on the yield or cost-effectiveness of diagnostic strategies for silent cerebrovascular disease, probably because the benefit of risk factor modification in this clinical setting is uncertain because it has not yet been subject to clinical trials (see also the subsequent 2 sections on stroke prevention in patients with silent brain infarct and in patients with WMH).

Prevention of Symptomatic Stroke in Patients With Silent Brain Infarcts

In this section, we discuss symptomatic stroke risk in patients with silent brain infarcts (from observational or randomized trials), controlled trials of vascular risk reduction in patients with silent brain infarcts, and suggestions for strategies to prevent ischemic stroke in patients with silent brain infarcts. Our discussion emphasizes silent brain infarcts in the general population and does not focus primarily on specialized conditions or circumstances that provoke silent infarcts such as sickle cell disease and aortic and mitral valve replacement surgery or other interventions.

Information From Population-Based and Other Observational Studies About the Risk of Future Symptomatic Stroke When There Are Silent Brain Infarcts

Four population-based studies in the United States and Europe have reported the incidence of new symptomatic stroke in individuals with versus without MRI-defined silent brain infarcts at baseline, with mean follow-up ranging from 3 to 15 years (Table 5). With age, sex, and vascular risk factors controlled for, the presence of silent brain infarcts was an independent predictor of future stroke in all of the studies, with hazard ratios (HRs) ranging from 1.5 to 3.3. In the 2 studies with mean age of 62 years, the unadjusted absolute increased risk was 0.34%/y and 1.2%/y. In the 2 studies with a mean age in the early 70s, the unadjusted absolute increased risk was 1.6%/y and 2.3%/y. The higher absolute annual risks in older individuals reflect the fact that older age is also a risk factor for symptomatic stroke independently of the presence or absence of silent brain infarcts.

A larger number of silent brain infarcts at baseline was associated with higher risk of subsequent symptomatic stroke.[13] Most incident strokes were ischemic (81%–89%), not hemorrhagic (11%–19%),[10,12,13,108] similar to the distribution seen in all symptomatic stroke in the population. The studies did not accrue enough incident events to analyze risk for ischemic stroke separately from that for hemorrhagic stroke, nor did they have enough power to analyze whether the location and type of baseline silent brain infarct (eg, whether lacunar or cortical) were associated with the type of recurrent stroke.

The association between silent brain infarcts and future stroke risk has also been investigated in observational studies in specific settings of increased cardiovascular risk. A systematic review of studies of silent brain infarction in patients with asymptomatic carotid artery stenosis showed that nonlacunar ipsilateral silent CT brain infarctions, potentially caused by arterio-arterial embolism, were associated with future symptomatic stroke risk (pooled OR, 4.6; 95% CI, 3.0–7.2; $P<0.0001$).[103]

Information From Randomized Controlled Trials About the Risk of Future Symptomatic Stroke When There Are Silent Brain Infarcts

Several recurrent stroke prevention clinical trials provide important information about silent brain infarcts and subsequent symptomatic stroke. The EAFT (European Atrial Fibrillation Trial) showed that the presence of silent brain infarcts was associated with an increased risk of vascular events in general (HR, 1.5; 95% CI, 1.2–1.9; $P=0.001$) and recurrent stroke in particular (HR, 1.7; 95% CI, 1.2–2.3; $P=0.002$).[97] In a substudy of PROGRESS (Perindopril Protection Against Recurrent Stroke Study), perindopril-based blood pressure–lowering therapy did not decrease the risk of new silent brain infarcts (12.5% in the treatment group had new infarcts compared with 15.0% in the placebo group; $P=0.34$) or brain atrophy. Rates of symptomatic stroke recurrence in patients with versus without silent brain infarcts were not provided.[113] However, this substudy in a portion of the PROGRESS participant groups probably lacked statistical power to detect an effect. In the PRoFESS (Prevention Regimen for Effectively Avoiding Second Strokes) imaging substudy, after a mean

follow-up of only 2.5 years, silent brain infarction was not shown to be an independent risk for recurrent stroke, other vascular events, or a higher mortality.[114] Ongoing aspirin and other stroke prevention trials have the potential to expand our knowledge of the prevention of silent brain infarction.[115,116]

Vascular Risk Reduction in Patients With Silent Brain Infarction to Prevent Symptomatic Stroke

There is a paucity of information from controlled, clinical trials on the prevention of symptomatic stroke in patients with silent brain infarction. A number of observational studies and scientific statements call for additional information in this area but do not provide high-level evidence to guide the clinician.[6,91]

A guideline from the AHA recommends that it is reasonable to implement programs to systematically identify and treat risk in individuals at risk of stroke.[91] The obvious targets for prevention of silent brain infarction such as conventional cardiovascular risk factors have been identified.[6,91] Of note, significant effort has been leveraged to identify which patients will benefit from intervention for asymptomatic carotid artery stenosis, which could reduce risk of silent brain infarction and symptomatic stroke.[117] Diagnostic assessments for such exploration are reviewed elsewhere.[117]

Suggestions and Considerations for Clinical Practice

We suggest that it may be reasonable to follow AHA/ASA guidelines for primary stroke prevention[90] to prevent symptomatic stroke in individuals with silent brain infarction who have not had a TIA or symptomatic stroke. The effectiveness of aspirin or other antithrombotic therapies in preventing symptomatic stroke or recurrent silent brain infarction in patients with silent brain infarction has not been established. Careful elicitation of a history of prior symptoms of TIA or stroke in patients with silent brain infarction is important because such symptoms may be missed in more casual examination. If such symptoms are detected, the patient may be classified in a recurrent stroke prevention category, and recurrent stroke prevention therapies should be administered.

The clinician should be aware that silent brain infarction predicts an increased risk of subsequent symptomatic stroke even after known vascular risk factors are controlled for and that this risk has been documented in the general population and in patients with asymptomatic carotid stenosis. It is reasonable for the clinician to consider this information when making decisions about the benefits of statin therapy, choice of antithrombotic in patients with AF, revascularization therapy in patients with asymptomatic carotid stenosis, or treatment of hypertension. However, the clinician should be aware that it is currently unproven whether information on the presence or absence of silent brain infarcts improves the prediction of future symptomatic stroke compared with existing risk prediction tools such as the Pooled Cohort Equations[118] for determining eligibility for statin therapy[119] or CHA_2DS_2-VASC score for patients with AF, which do not include imaging information. Similarly, there are no clinical trial data to show whether the benefit of asymptomatic carotid revascularization differs in patients with or without silent brain infarction. It is not clear whether silent brain infarcts should be considered equivalent to symptomatic stroke for determining blood pressure targets.

Areas for Further Investigation

Prevention of a symptomatic stroke in the presence of existent silent brain infarct has not been a major focus of clinical trials. The most useful new information would come from clinical trials of antithrombotic and other stroke prevention strategies in patients with silent brain infarction without a history of symptomatic stroke. Some stroke and cardiovascular trials have incorporated substudies with neuroimaging secondary end points. Such substudies can also provide information on the effectiveness of the study interventions in patients with and without silent brain infarction, although they will probably lack statistical power because of the limited number of patients with silent brain infarcts.

Research is needed on the added value of silent brain infarcts for predicting risk of cardiovascular events, not only stroke, in the general population. Current research shows that silent brain infarcts are associated with the risk for future symptomatic stroke when known vascular risk factors are controlled for. Future research should address whether adding information on silent brain infarcts to risk prediction tools (such as the Pooled Cohort Equations[118] and CHA_2DS_2-VASC scores) provides clinically meaningful improvements in the discrimination of patients with versus without future cardiovascular events. If so, then modified versions of these scores could be derived for use in patients when neuroimaging information is available. Because incident events are relatively uncommon in the general population, studies to derive risk prediction scores will require large sample sizes and could potentially be facilitated by pooling data from existing studies.

Prevention of Symptomatic Stroke in Patients With WMHs of Presumed Vascular Origin

WMHs are very commonly identified on brain CT and MRI scans of elderly people and have been associated with stroke, cognitive decline, depression, and gait impairment.[36] This section reviews the scientific evidence for stroke prevention strategies in patients without a history of stroke who have excessive WMHs for age on brain imaging done for unrelated reasons. We discuss stroke risk in patients with WMHs and vascular risk reduction in WMH.

Information From Population-Based and Other Studies About the Risk of Future Symptomatic Stroke Associated With WMHs

A meta-analysis of 6 population-based studies reported a significant association of WMHs with risk of future stroke (HR, 3.1 for high burden of WMH versus low burden; 95% CI, 2.3–4.1; $P<0.001$; Figure 8).[17] Of note, the studies included in that meta-analysis used different scales and cut points to categorize WMHs, most often comparing individuals across tertiles—or other distribution measures derived from the study population concerned—of WMH severity. This complicates the translation of the reported HR to a risk estimate for an individual patient with WMH because the risk at specific WMH

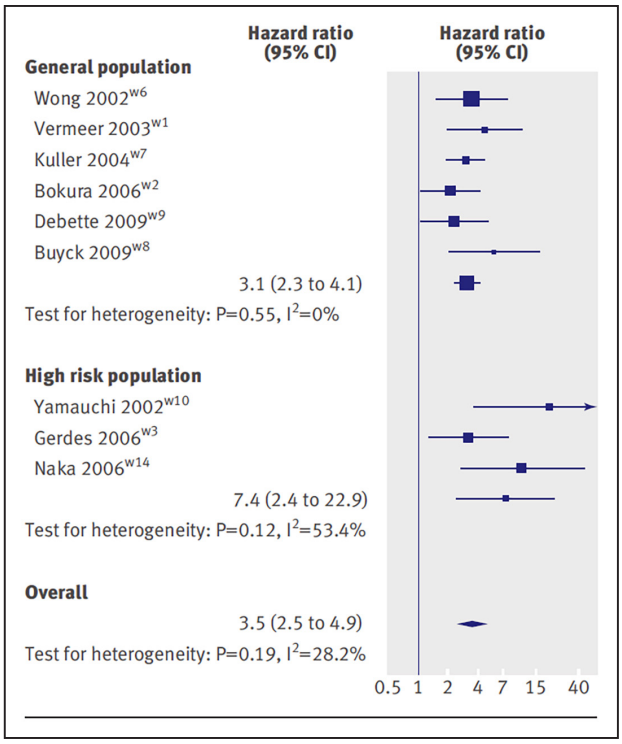

Figure 8. Hazard ratio for future symptomatic stroke in individuals with a high burden of white matter hyperintensities (WMHs). Data were pooled from studies that categorized WMH, comparing the highest category with the lowest category. From Debette and Markus.[17] Copyright © 2010, The Authors. This is an Open Access article distributed under the terms of the Creative Commons Attribution Non-commercial License, which permits use, distribution, and reproduction in any medium, provided the original work is properly cited, the use is non commercial and is otherwise in compliance with the license.

thresholds was not defined. As a result, the pooled data are currently insufficient to determine annualized absolute stroke risks at different levels of WMH. There are insufficient data to determine the shape of the curve of the association between WMH and stroke risk, and it is not currently known whether there is a minimum WMH threshold below which there is no longer an association between WMH and stroke risk, that is, in which a variation in WMH volume can no longer be considered clinically relevant for stroke prediction.

Although the pathophysiology of WMH remains unclear and may be multifactorial, associations with vascular risk factors and symptomatic stroke[120,121] suggest that WMH may serve as a proxy measure of cerebral small vessel disease. However, there is insufficient evidence to conclude that WMH should be considered an equivalent of symptomatic stroke in stroke prevention strategies. Hence, in patients with an increased WMH burden but no history of a vascular event, guidelines for the secondary prevention of stroke are of unclear relevance, but guidelines for the primary prevention of stroke would certainly apply. Guidelines for the primary prevention of stroke from the AHA/ASA recommend that it is reasonable to use a risk assessment tool such as the AHA/ACC CV Risk Calculator[122] because these tools can help identify individuals who could benefit from therapeutic interventions and who may not be treated on the basis of any single risk factor.[91] However, these calculators do not include WMH as a marker of possible risk. Hence, individual clinical judgment must be exercised when considering whether the amount of WMH is an important modifier of the future risk of stroke in an individual patient.

Vascular Risk Reduction in Patients With WMH to Prevent Symptomatic Stroke

As indicated in the previous section, vascular risk reduction strategies in patients with an increased burden of WMH are probably best based on available evidence-based guidelines for the primary prevention of stroke, taking into account the increased risk of stroke conveyed by the WMH, in light of the overall risk profile of the patient.

Because the absolute risk of a future stroke is higher in patients with than in those without WMH, the numbers needed to treat for preventive treatment would be lower for patients with than for those without WMH if the relative risk reduction of a certain treatment would be the same in patients with and without WMHs. However, this is not likely to be the case for all treatments that can be considered for the primary prevention of stroke. Currently, there are no solid data on absolute or relative reductions of stroke risk specifically for patients with WMH.

There are indications from observational studies, however, that active blood pressure–lowering therapy[59] can slow the progression of WMH in patients at increased vascular risk. WMH progression has also been evaluated in MRI substudies of several randomized controlled trials (RCTs) of vascular risk reduction. In the PROGRESS MRI substudy of 192 patients with symptomatic stroke, the active treatment (perindopril plus indapamide) resulted in a 11.2–mm Hg reduction in systolic blood pressure compared with placebo, and treated patients were less likely to have new WMHs seen on follow-up MRI at a mean of 3 years.[123] However, the addition of telmisartan to usual blood pressure treatment, which reduced mean systolic blood pressure by 3 mm Hg, did not reduce WMH progression in the PRoFESS trial.[124] For statin treatment, trials have provided conflicting evidence as to whether statin treatment reduces WMH progression.[125–127] Intensive glucose-lowering therapy in patients with type 2 diabetes mellitus did not reduce WMH progression and in fact was associated with higher WMH progression for unclear reasons.[128] Vitamin B and folate therapy did not reduce the progression of WMH in the VITATOPS study (Vitamins to Prevent Stroke), although a significant reduction in WMH progression (0.3 versus 1.7 cm^3; P=0.04) was detected in patients with severe WMH at baseline.[129] Finally, a small RCT (65 patients) in patients with Alzheimer disease showed that patients randomized to multimodal vascular care—consisting of algorithms for the management of diet, physical exercise, hypertension, and hypercholesterolemia, as well as aspirin, pyridoxine, and folic acid—had less change in WMH at 2 years.[130]

The clinical relevance of these RCT results on WMH progression remains uncertain, however, because the reduction in WMH needed to produce clinically relevant benefits in cognition or stroke risk reduction is unclear. Furthermore, all of these trials to prevent WMH progression were done in subsets of patients participating in larger RCTs, had a relatively short

follow-up, and probably lacked statistical power to link WMH progression with clinical events.

Another issue to consider is potential harm of treatment in relation to the presence of WMHs. Although no studies on the primary prevention of stroke provide data on potential harm in relation to WMH burden, data from post hoc analyses in secondary prevention studies show that patients with WMHs may be at increased risk of ICH when treated with antithrombotic agents. Severe WMH was an independent predictor of anticoagulation-related hemorrhages in SPIRIT (Stroke Prevention in Reversible Ischemia Trial), which assessed secondary prevention in patients with arterial stroke (HR, 2.7; 95% CI, 1.4–5.3).[131] Other secondary prevention trials with antithrombotic agents have not provided stratified analyses on bleeding risk according to WMH presence. Of note, in patients with early Alzheimer disease, aspirin use may be linked to an increased risk of ICHs. In the EVA study (Evaluation of Vascular Care in Alzheimer's Disease), patients with Alzheimer disease and ≥1 manifestations of cerebral small vessel disease (WMHs or infarcts) were randomized to multimodal vascular care, including aspirin, or placebo.[132] Among the 65 patients randomized to aspirin, 3 had fatal ICH. A pooled analysis of EVA with the Aspirin in Alzheimer's Disease trial showed a nonsignificantly elevated risk for ICH in aspirin users with Alzheimer disease (HR, 7.63; 95% CI, 0.7–81.7; P=0.09).[133] These findings, although not providing direct evidence for an unfavorable benefit/risk ratio for the use of antithrombotic agents for the primary prevention of stroke in patients with WMH, suggest that some caution is warranted. Another potential issue is the risk for falls in patients with too rigorous a reduction of blood pressure because WMHs are associated with gait and balance disturbances.[134]

Suggestions and Considerations for Clinical Practice

We suggest that it may be reasonable to follow AHA/ASA guidelines for primary stroke prevention to prevent symptomatic stroke in individuals with WMHs.[91] The clinician should be aware that higher WMH burden predicts an increased risk of subsequent symptomatic stroke in the general population, even after controlling for known vascular risk factors. However, WMHs are not incorporated into existing clinical risk prediction tools such as the AHA/ACC CV Risk Calculator or the CHA_2DS_2-VASC score for predicting ischemic stroke risk in patients with AF. The effectiveness of aspirin or other antithrombotic therapies in preventing symptomatic stroke in patients with WMHs has not been established. Some RCTs suggest higher rates of symptomatic intracranial hemorrhage in stroke patients or patients with dementia with high WMHs treated with antithrombotics (see the preceding section for details), and the pathophysiology of WMH remains uncertain and may be mediated by mechanisms other than thrombosis. Therefore, we suggest that WMH alone, in the absence of other vascular risk factors, is probably not a sufficient reason to start antithrombotic therapy to prevent stroke. On the other hand, the presence of WMH should not dissuade the clinician from prescribing antithrombotic therapy when there is a clear guideline-based indication. It is possible that the absence or presence of concomitant CMBs could identify subpopulations among individuals with WMH who are at lower versus higher risk of hemorrhage with antithrombotic therapies; however, this has not been specifically studied. Blood pressure lowering appears to be the most promising therapy for preventing WMH; however, it is not clear whether the presence of WMH should influence the choice of blood pressure targets in the elderly.

Areas for Further Investigation

Patients with WMHs have not been subjected to RCTs of vascular risk reduction except as substudies of larger trials. More data are needed to determine the relationship between the amount of reduced WMH progression and the clinical impact, including on stroke risk and cognitive impairment.

Future studies should address whether WMH confers clinically meaningful added predictive utility compared with commonly used stroke and cardiovascular disease prediction tools such as the AHA/ACC CV Risk Calculator and CHA_2DS_2-VASC scores. More data are needed on the relationship between baseline WMH and incident stroke risk, including whether the risk increases linearly across the entire range of WMHs or whether there are nonlinear effects. Because incident events are less common than prevalent events, large studies or pooling of data from existing large population-based studies will be needed to precisely define risk throughout the typical range of WMHs, including whether there is a minimum threshold below which WMH is no longer relevant to stroke risk and can be considered a benign consequence of aging.

Anticoagulation and Other Medical Therapies in Patients With Silent CMBs

Anticoagulation with the vitamin K antagonist warfarin or non–vitamin K oral anticoagulants (NOACs) such as dabigatran, apixaban, rivaroxaban, and edoxaban[135] is a recommended treatment of nonvalvular AF (NVAF) for primary stroke prevention when stroke risk is sufficiently high[91] and for secondary prevention after TIA or stroke.[90] These recommendations, mostly with Class I treatment effect, are driven by the extraordinary effectiveness of anticoagulants for preventing NVAF-associated thromboembolic stroke. Adjusted-dose warfarin with a target international normalized ratio of 2 to 3 eliminates much of the excess risk of ischemic stroke associated with NVAF, with a risk ratio (RR) reduction of 64% (95% CI, 49–74) for stroke occurrence relative to placebo and 39% (95% CI, 22–52) relative to antiplatelets.[136] Warfarin treatment for NVAF is also associated with reduced all-cause mortality[136] and reduced ischemic stroke severity.[137–139] Anticoagulation with NOACs appears at least equally effective as anticoagulation with warfarin for ischemic stroke prevention. A meta-analysis of 42 411 NVAF trial subjects assigned to the NOACs dabigatran, apixaban, rivaroxaban, and edoxaban versus 29 272 assigned to warfarin found nonsignificantly fewer ischemic strokes with NOAC treatment (RR versus warfarin, 0.92; 95% CI, 0.83–1.02).[140]

The major risk of anticoagulation is intracranial hemorrhage. Among warfarin-treated patients with NVAF in the

Kaiser Permanente of Northern California healthcare system followed up for 15 370 person-years,[141] intracranial hemorrhage (71% intracerebral, 21% subdural) occurred at an annualized rate of 0.47% with discharge outcomes of death in 42% and major disability in 34%, accounting for ≈90% of bleeding-related deaths and 95% of major disability in this cohort. In contrast, intracranial hemorrhage is relatively less frequent in patients taking NOACs compared with patients taking warfarin. A meta-analysis of the NOAC trials showed reduced hemorrhagic stroke (RR, 0.49; 95% CI, 0.38–0.64) or intracranial hemorrhage (RR, 0.48; 95% CI, 0.39–0.59) relative to warfarin but increased gastrointestinal bleeding (RR, 1.25; 95% CI, 1.01–1.55).[140] Although concerns have been raised because of the absence of established reversal treatment for NOACs,[142] mortality after intracranial hemorrhage was no higher on dabigatran or rivaroxaban than on warfarin in the randomized trials.[143,144]

The key clinical question is, Do CMBs in patients with NVAF confer sufficient risk for ICH to offset the substantial benefits of anticoagulation? Unfortunately, no studies to date have determined the effect of microbleeds on ICH risk specifically in the setting of anticoagulation. However, some longitudinal studies have investigated the association between baseline microbleeds and subsequent stroke in stroke patients or in the general population, not limited to patients taking anticoagulation. A meta-analysis of 3067 patients with baseline ischemic stroke or TIA from all causes, 29% of whom had microbleeds, found that the patients with microbleeds had a pooled OR for any type of future stroke of 2.25 (95% CI, 1.70–2.98) relative to patients without microbleeds.[145] Among studies that distinguished between future stroke types, the OR for ICH was 8.52 (95% CI, 4.23–17.18) and for ischemic stroke was 1.55 (95% CI, 1.12–2.13). Two Japanese studies have been performed in subjects not selected for prior stroke or TIA. A study of 698 subjects scanned in Osaka, 17% with microbleeds, found multivariable-adjusted HRs of 1.48 (95% CI, 0.63–3.45) for future ICH and 11.77 (95% CI, 2.95–46.82) for future ischemic stroke.[146] A more recent study of 2102 volunteers scanned in Izumo, 4.4% with microbleeds, reported a multivariable-adjusted HR of 50.2 (95% CI, 16.7–150.9) for future ICH and 4.48 (95% CI, 2.20–12.22) for future ischemic stroke.[147] However, even the elevated HR for future ICH in this study represented a relatively low absolute event rate (≈2 to 3 incident ICHs per 1000 person-years among CMB-positive subjects).

As suggested by the wide range of values obtained across these analyses, there is likely to be substantial heterogeneity among the various subjects classified as microbleed positive. Factors contributing to this heterogeneity include differences between Asian and Western populations[145]; different T2*-weighted methods, which can substantially affect CMB detection[5]; and differences in the number of microbleeds per subject, with evidence suggesting higher subsequent ICH risk at higher total microbleed counts.[148,149] Other likely sources of heterogeneity are the different types of cerebral small vessel diseases responsible for microbleeds. The age- and hypertension-related process of arteriolosclerosis commonly causes microbleeds in deep hemispheric gray matter and brainstem, whereas CAA is typically associated with microbleeds in a strictly lobar brain distribution[5] and higher rates of ICH recurrence.[150,151] A recent hospital-based analysis of 60 subjects diagnosed with probable CAA on the basis of multiple (median, 10) strictly lobar microbleeds found an incidence of 5 symptomatic ICHs per 100 person-years (95% CI, 2.6–8.7),[152] suggesting that the risk of future ICH in selected subgroups of microbleed-positive individuals can be quite high.

In the absence of controlled studies of anticoagulation in the setting of microbleeds, decision-analysis models provide a framework for understanding the decision "tipping point," that is, the threshold at which the risks of anticoagulation outweigh its benefits. A Markov state transition analysis based on a subject with NVAF with a typical thromboembolic stroke risk (4.5%/y untreated) found that anticoagulation with warfarin would result in better predicted outcome than aspirin or no antithrombotic treatment unless the individual's microbleed status carried a >16-fold increased hazard for ICH.[153] The tipping point moves to lower threshold values in individuals at particularly low thromboembolic stroke risk[153]; conversely, a higher threshold would apply if the presence of microbleeds confers increased ischemic stroke risk, as suggested by current data.[145,154,155] Anticoagulation also is increasingly preferred when lower intracranial hemorrhage risks[156] are assumed, as observed in the NOAC trials.[140]

Risks for ICH in patients taking antiplatelet drug therapy or statins are likely considerably lower than for anticoagulation. According to data from the Antithrombotic Trialists Collaboration,[157] the stratified OR for hemorrhagic stroke in antiplatelet drug users is 1.22 (SE, 0.10). The use of high-dose atorvastatin was associated with increased ICHs in the SPARCL trial (Stroke Prevention by Aggressive Reduction in Cholesterol Levels; HR, 1.68; 95% CI, 1.09–2.59)[158] but not in a subsequent meta-analysis of all statin trials (OR, 1.08; 95% CI, 0.88–1.32).[159] The degree to which these risks may be increased in the presence of microbleeds has not been defined by clinical trials.

A recent population-based study shows that microbleeds are associated with increased risk for future ischemic stroke and hemorrhagic stroke.[160] In that study, there were overall more ischemic strokes than hemorrhagic strokes in the individuals with microbleeds. The increased risks were independent of silent brain infarcts and WMHs. Patients with a pattern of lobar-only microbleeds, potentially indicating underlying CAA, were at risk for ICH but not ischemic stroke, whereas individuals with other microbleed patterns were at risk for both ischemic stroke and hemorrhagic stroke. There are currently no published clinical trials for ischemic stroke prevention in patients with microbleeds.

Suggestions and Considerations for Clinical Practice

Current data do not convincingly indicate that the presence of microbleeds (without prior ICH) confers enough risk for future ICH to tip the clinical decision away from anticoagulation in patients with NVAF for whom it is otherwise indicated. The suggestion that CMB-positive patients may be at increased risk for ischemic and hemorrhagic stroke further reinforces this impression. We suggest that it is reasonable

to proceed with oral anticoagulation despite the detection of microbleeds when anticoagulation is otherwise indicated for NVAF according to existing primary or secondary stroke prevention guidelines. It is therefore reasonable not to perform routine MRI screening of patients with NVAF.

The lower risk of intracranial hemorrhage associated with NOAC anticoagulation suggests that these agents may be useful in patients considered at increased ICH risk on the basis of their microbleed status. Therefore, we suggest that, for patients with NVAF in whom anticoagulation is indicated but who are considered at particularly high risk of future ICH on the basis of microbleed number and location, it may be reasonable to administer dabigatran, rivaroxaban, apixaban, or edoxaban in preference to warfarin. Another alternative to warfarin anticoagulation that might be considered is percutaneous closure of the left atrial appendage,[161] as suggested in AHA/ASA guidelines for the management of spontaneous ICH.[112]

Other guidelines suggested for the prevention of ICH recurrence in patients with spontaneous ICH[112] are also reasonable considerations for patients with CMBs. These guidelines for patients with ICH include blood pressure control and no restriction on the use of statins. It is reasonable to avoid antiplatelet agents when there is no specific cardiovascular or cerebrovascular indication but otherwise to use them according to currently recommended indications.

Finally, one should not overlook the fact that patients with microbleeds are also at increased risk for ischemic stroke. We suggest that it may be reasonable to follow AHA/ASA guidelines for primary stroke prevention to prevent symptomatic stroke in individuals with microbleeds.[91] We suggest that the presence of microbleeds alone, in isolation of other findings and patient characteristics, does not warrant the initiation of antiplatelet medications or statin therapy for preventing stroke.

Areas for Further Investigation

Currently, there are no direct measurements of ICH risk among microbleed-positive individuals treated with warfarin or NOACs. Such data could come from registries or cohort studies of anticoagulated patients with baseline MRI information. There are similarly no prospective measurements of ICH risk associated with antiplatelet or statin treatment of microbleed-positive individuals. There are no clinical trials of vascular risk reduction to prevent ischemic or hemorrhagic stroke in individuals with microbleeds. It would be useful to add MRI substudies to current and future trials of oral anticoagulants to investigate whether particular microbleed-positive subgroups such as individuals with many strictly lobar microbleeds are at higher ICH risk and thus may cross the ICH risk threshold for avoiding anticoagulation.

Safety of Intravenous Thrombolysis and Acute Ischemic Stroke Reperfusion Therapy in Patients With Silent CMBs

Intravenous thrombolysis and endovascular therapy for patients with acute ischemic stroke have proven benefits but can cause ICH. Predicting which patients may have an ICH can guide treatment decisions. Microbleeds are identified on T2* or susceptibility-weighted imaging MRI brain scans,[5] are associated with ICH,[145] and may act as a predictor of post–tissue-type plasminogen activator (tPA) symptomatic intracranial hemorrhage (sICH). Here, we assess whether CMBs are associated with symptomatic sICH after acute stroke therapy and whether the presence of microbleeds should influence the decision to administer intravenous tPA or endovascular therapy to patients with acute ischemic stroke.

Several observational studies have investigated whether microbleeds predict sICH after acute stroke reperfusion therapy. A recent scientific statement from the AHA/ASA found no evidence that the risk for sICH was increased in patients with microbleeds and recommended that "systemic intravenous rtPA [recombinant tPA] administration in these patients is therefore reasonable."[162] However, subsequent to this recommendation, a more recent updated meta-analysis of observational trials was published,[163] analyzing data from 10 eligible studies (2028 patients) that studied the association between baseline microbleeds and postthrombolysis sICH. Eight studies provided data for intravenous tPA,[164–171] and 2 other studies included patients with endovascular acute ischemic stroke therapy or a mixture of methods.[172,173] The crude prevalence of microbleeds in all 10 studies before thrombolysis was 23%.[163] The rate of sICH in patients with microbleeds was 8.5% (95% CI, 6.1–11.4) and in patients without microbleeds was 3.9% (95% CI, 3–5). There was no significant heterogeneity between studies. A meta-analysis showed that the presence of CMBs (versus the absence of microbleeds) was associated with an increased risk of postthrombolysis sICH (OR, 2.26; 95% CI, 1.46–3.49; $P<0.001$).[163] Similarly, CMBs were associated with an increased risk of sICH when studies reporting only intravenous thrombolysis were combined (OR, 2.87; 95% CI, 1.76–4.69; $P<0.0001$).[163] The authors could not exclude residual confounding from study design heterogeneity. Most recently, Turc et al[174] found that, after adjustment for other predictors, microbleed burden in 717 patients did not predict sICH or poor outcome at 3 months (OR, 1.03; 95% CI, 0.96–1.11 per 1-CMB increase; $P=0.37$) after intravenous thrombolysis for ischemic stroke.

Endovascular thrombectomy with clot retrieval devices is an alternative acute ischemic stroke treatment approach that does not necessarily require administration of a systemic thrombolytic. However, rates of sICH are similarly high in patients treated with endovascular therapy alone and in patients who receive either intravenous thrombolysis or combination therapy, suggesting that avoiding intravenous thrombolysis does not eliminate the risk of sICH after reperfusion.[175] One study found that, in 206 patients treated with thrombectomy for acute ischemic stroke, baseline microbleeds did not predict parenchymal hematoma formation (rate with microbleeds, 16%; rate without microbleeds, 19%) or modified Rankin Scale score at discharge.[176] Other studies did not report thrombectomy subgroups separately.[167] There are insufficient data to assess associations between the presence of baseline CMBs and sICH or outcome in patients treated with intra-arterial thrombolysis.[166,173]

No randomized trials have been published that address whether CMB identified before intravenous thrombolysis should influence the decision to administer thrombolysis.

In summary, CMBs may modestly increase the risk of postthrombolysis sICH, but this relationship requires clarification, especially with respect to the burden rather than the simple presence or absence of microbleeds. In the absence of RCT data, it is not possible to determine whether this possibly increased risk of sICH in patients with microbleeds outweighs the known therapeutic benefits of thrombolysis.

Suggestions and Considerations for Clinical Practice

In contrast to prior evidence summarized in a recent AHA/ASA scientific statement, newer evidence suggests that patients with ≥1 microbleeds are at increased risk for symptomatic ICH after systemic thrombolysis, with an approximate doubling of the risk.[163] However, there are insufficient data to show whether this increased risk for ICH outweighs the known, strong benefit of thrombolysis. Accordingly, we suggest that the prior AHA/ASA recommendation[162] remains appropriate and that it is still reasonable to administer systemic intravenous tPA in patients with ≥1 microbleeds. We suggest that clinicians should not withhold endovascular acute ischemic stroke therapy such as thrombectomy on the basis of the presence of microbleeds in an otherwise eligible patient. Because there are few data on the relationship between microbleeds and complications of endovascular thrombectomy for acute ischemic stroke, clinicians should consider a strategy of proceeding directly to thrombectomy without thrombolysis to be an unproven approach in these patients.

Areas for Further Investigation

The most important question is whether clinical disability and mortality outcomes are different in patients with and those without microbleeds treated with thrombolysis or endovascular thrombectomy. This information would clarify whether the benefits of reperfusion therapy outweigh the moderately increased risk of ICH. Ideally, these data would come from randomized trials. However, it is unlikely that such trials will be done because of the paucity of acute stroke centers that currently use MRI for acute stroke imaging. Instead, data could come from analysis of observational studies and thrombolysis registries with baseline MRI information and 90-day outcomes, as has been done in other circumstances in which thrombolysis is associated with increased risk. For example, analysis of the Safe Implementation of Treatments in Stroke-Monitoring International Stroke Thrombolysis Registry suggests that thrombolysis is still effective in patients taking antithrombotic drugs at the time of their stroke because there was no increase in disability and mortality despite the observation that prestroke antiplatelet drug use was associated with a 1.74-fold increased odds of ICH.[177]

Further stratification of risk associated with the number of microbleeds should also be possible and could lead to the identification of number thresholds at which risk actually outweighs benefits. In addition to obtaining precise data on the relationship between CMB number and ICH risk, it would be useful to assess whether relationships are modified by CMB location (including lobar versus deep and anterior versus posterior). A pattern of lobar-only microbleeds may be indicative of CAA,[111] which is associated with higher ICH recurrence in patients with primary, non–thrombolysis-associated ICH. However, it is not known whether this potential CAA pattern of microbleeds is associated with risk for ICH after thrombolysis. Finally, more research is needed to understand whether microbleeds are associated with different patterns or severity of postthrombolysis ICH. It has been hypothesized that microbleeds may be associated with a higher risk of remote ICH rather than ICH resulting from hemorrhagic transformation within the infarcted tissue because microbleeds reflect a more diffusely distributed hemorrhage-prone small vessel vasculopathy.

Population Screening for Silent Cerebrovascular Disease

Although the progression of silent cerebrovascular disease is associated with greater cognitive decline in observational studies, it remains unproven whether preventing its progression also prevents cognitive decline. In this context, it is unclear whether MRI screening in the population or subgroups to identify those at risk is warranted. To date, no study has addressed the utility of screening for silent cerebrovascular disease with regard to reduced adverse health events or cost-effectiveness.

There are several challenges to screening for silent cerebrovascular disease. First, the lack of evidence for an established medical treatment for its progression makes screening difficult to justify. Second, although silent cerebrovascular disease clearly confers an increased risk of stroke and dementia, the absolute risk increase is small and may not justify the high cost of screening in the general population.

Even in children with sickle cell anemia, in whom silent brain infarction is highly prevalent and is associated with significant cognitive and academic morbidity and increased risk of future stroke, no evidence-based approach has been developed to systematically identify children with silent cerebral infarcts, despite evidence that transfusion reduces the risk of recurrent silent brain infarction.[178,179] In light of the limited evidence, recent recommendations did not support neuroimaging screening in asymptomatic children, adolescents, and adults with sickle cell disease.[180]

Suggestions and Considerations for Clinical Practice

We suggest that screening for silent brain infarcts or other forms of cerebrovascular disease is not warranted in asymptomatic individuals. Neuroimaging investigation should be reserved for patients with potential manifestations of clinically unrecognized cerebrovascular disease such as focal neurological symptoms or cognitive decline.

Areas for Further Investigation

To determine the benefits and costs of screening the asymptomatic population, it will be necessary to have RCT data demonstrating that silent cerebrovascular disease progression can be reduced and that this reduction decreases the incidence of clinically meaningful end points such as symptomatic stroke or cognitive decline. Research to identify people at higher risk

for silent cerebrovascular disease may allow targeted neuroimaging screening of higher-risk individuals, thereby improving cost-effectiveness by avoiding costly screening scans in individuals unlikely to have lesions.

Conclusions

We found consistent evidence that silent cerebrovascular disease is a very common problem of aging and that infarcts and WMHs are strongly associated with future symptomatic stroke risk (2- to 3-fold increase in relative risk) even after controlling for vascular risk factors such as hypertension. In patients with CMBs, there was evidence of a moderately increased risk of symptomatic intracranial hemorrhage in patients treated with thrombolysis for acute ischemic stroke but little prospective evidence on the risk of symptomatic hemorrhage in patients on anticoagulation. We found little evidence for how to investigate or manage patients with silent cerebrovascular disease, including that there were no prospective RCTs targeted specifically to this patient population. Therefore, formal recommendations for care cannot be provided; instead, we describe clinical considerations and offer suggestions for future research. In light of the limited evidence for the management of silent cerebrovascular disease, population screening is not justified.

Silent brain infarcts are the most frequently identified incidental finding on brain scans.[3,89] With >1.5 million brain scans performed each year for headache alone in the United States,[181] many patients will have incidentally detected silent cerebrovascular disease. This unintended screening has potential benefit if it can be used to target health-promoting interventions to patients with silent cerebrovascular disease, but it also has potential risks if it leads to excessive testing or overtreatment, contributing to rising healthcare costs or even causing harm. Additionally, detection of silent cerebrovascular disease may have implications in other clinical settings such as symptomatic stroke. For example, there is clinical concern about the safety of antithrombotic medications in ischemic stroke patients whose brain MRI additionally shows silent CMBs.[182]

To date, there has been little consensus on the clinical relevance of incidentally detected silent cerebrovascular disease in routine practice or how it should be managed. The 2013 AHA/ASA statement on the definition of stroke noted that patients with silent cerebrovascular disease would have been included in primary prevention trials and that there was a paucity of data from clinical trials targeted specifically at patients with silent cerebrovascular disease.[6] Therefore, the statement suggests that vascular risk factors in patients with silent cerebrovascular disease should be managed according to existing primary prevention guidelines; however, these suggestions were not accompanied by systematic literature reviews or formal AHA/ASA recommendations.

Accurate and reliable radiological reporting using consensus terms understood by radiologists and nonradiologists alike will be essential to identify patients with silent cerebrovascular disease for appropriate management. We suggest definitions, terms, and reporting standards for silent cerebrovascular disease that are based on and consistent with past AHA/ASA scientific statements[6,15] and previously published consensus standards.[16,22] More research is needed on the accuracy and reliability of reporting in routine clinical practice and on how technical factors such as MR field strength and sequence parameter choices affect sensitivity and specificity.

Patients with silent brain infarcts and extensive WMHs are at increased risk of future symptomatic stroke independently of known vascular risk factors. Limited evidence suggests that silent brain infarcts are associated with increased risk of ischemic stroke in patients with asymptomatic carotid artery disease or AF. The clinician should keep this in mind when determining individual stroke risk reduction strategies. However, the effectiveness of specific risk reduction strategies, including the use of aspirin, has not been established by RCTs. Increasingly, cardiovascular care guidelines incorporate risk-based strategies. Examples include recommendations for anticoagulation based on high CHA_2DS_2-VASC score or statin therapy for patients at high risk[119] based on the Pooled Cohort Equations.[118] Silent brain infarcts or WMHs might plausibly improve ischemic stroke risk prediction because in epidemiological studies they are associated with increased risk even after controlling for vascular risk factors. However, longitudinal studies are needed to determine the degree to which silent brain infarcts and WMHs improve the discrimination of future stroke when added to these risk scores.

The safety of anticoagulation in patients with silent CMBs has been much debated.[182] However, there are no large, prospective studies to quantify the risk. Current evidence suggests that the risk for future ICH is not sufficiently high to outweigh the benefits of anticoagulation in patients with NVAF for whom it is otherwise indicated. The AHA/ASA guidelines for ICH provide recommendations for the clinical management of patients with AF and a history of symptomatic ICH.[112]

There is evidence that patients with silent CMBs are probably at increased risk of ICH when given thrombolysis for acute ischemic stroke on the basis of a meta-analysis of 10 studies. However, patient outcome data showing whether this potential increased risk outweighs the known, strong benefits of thrombolysis are lacking. Studies of other risk factors for thrombolysis-associated ICH have shown that the clinical benefits of tPA are maintained across a wide range of predicted or actual risks.[177,183] Accordingly we suggest that thrombolysis with tPA should not be withheld in patients with CMBs in whom it is otherwise indicated.

Our reviews identified many areas where new knowledge is needed to guide management. No RCTs have specifically targeted patients with silent cerebrovascular disease. However, conducting such RCTs may be challenging. In the general population, absolute risks for incident stroke are relatively low even in participants at higher relative risk, including those with silent brain infarcts; therefore, prevention RCTs will need to be large to capture enough symptomatic stroke events. Screening and recruitment of participants with silent brain infarcts also present challenges. Study-sponsored MRI screening may not be cost-effective because many screened patients will not have silent infarcts and therefore would not be eligible for the trial. On the other hand, identifying participants on the basis of clinical scans may yield a heterogeneous population (because of varying clinical indications for the scans). In routine clinical practice, the sensitivity of clinical radiology reporting and the frequency of disclosure of the incidental findings to the patient

are not clear. One approach would be to include silent brain infarcts as evidence of elevated cardiovascular and stroke risk in prevention trials, which are often targeted at high-risk populations. We note that recent trials of cardiovascular prevention have sometimes included evidence of subclinical cardiovascular disease as an entry criterion (eg, based on asymptomatic electrocardiographic findings),[184] and neuroimaging evidence of silent brain infarction or WMH would be the closest cerebrovascular analog to that approach.

Comparative-effectiveness research could be used to associate treatment strategies with outcomes in patients with silent cerebrovascular disease diagnosed on clinical neuroimaging. However, adoption of standardized radiological terms (such as those recommended by this statement) will first be needed so that radiological diagnoses can be reliably extracted from clinical reports.

Even in the absence of RCTs targeted specifically at patients with silent cerebrovascular disease, important new clinically relevant information can be generated from other RCTs and cohort studies that include neuroimaging assessment of silent cerebrovascular disease at baseline. Data from larger longitudinal cohort studies with more incident events will be useful to better quantify symptomatic stroke risk in patients with silent cerebrovascular disease, including the relationship between WMH load and risk. More data are needed on risk in specific clinical scenarios, including in patients with AF and asymptomatic carotid disease. Longitudinal cohort studies are needed to prospectively define the rate of future ICH in patients with CMBs treated with anticoagulation or who undergo endovascular thrombectomy for acute ischemic stroke. Cohort studies should be used to define stroke risk in individuals with more recently recognized manifestations of cerebral small vessel disease, including the clinical relevance of greater numbers of visible perivascular spaces. Finally, important information may be gained by embedding MRI substudies, with either baseline or baseline and follow-up MRI, in ongoing RCTs for the primary and secondary prevention of cardiovascular disease. Such substudies will be useful for identifying effect modification (ie, whether prevention strategies are more or less effective in participants with silent cerebrovascular disease) and to better define natural history (using data from control arms as appropriate).

Additional useful information could be derived from RCT substudies that include MRI at follow-up in addition to baseline. Such studies could provide valuable information on risk factors for incident silent brain infarcts, microbleeds, and WMH progression, including the effect of treatments. Because silent brain infarct prevalence and incidence are higher than for symptomatic stroke, it is possible that treatment effects on silent brain infarcts could be demonstrated with smaller sample sizes than would be required for symptomatic stroke end points. However, per-subject costs would be higher because of the need for scanning. More research is needed on the clinical benefits of preventing silent brain infarction before it can be considered a fully validated surrogate outcome measure.

Disclosures

Writing Group Disclosures

Writing Group Member	Employment	Research Grant	Other Research Support	Speakers' Bureau/ Honoraria	Expert Witness	Ownership Interest	Consultant/ Advisory Board	Other
Eric E. Smith	University of Calgary	McMaster University (blinded MRI readings for clinical trials and epidemiological studies)†; Canadian Institutes of Health Research†; Heart and Stroke Foundation of Canada†; Alzheimer Society of Canada†; Canadian Partnership Against Cancer†	None	None	None	None	None	None
Gustavo Saposnik	St. Michael's Hospital, University of Toronto	None	None	None	None	None	None	None
Geert Jan Biessels	University Medical Centre Utrecht (Netherlands)	Boehringer Ingelheim*	None	None	None	None	None	None
Fergus N. Doubal	University of Edinburgh	Alzheimer's Society (PI on trial testing nitrates and cilostazol following stroke)†	None	None	None	None	None	None
Myriam Fornage	University of Texas Health Science Center at Houston	None	None	None	None	None	None	None

(*Continued*)

Writing Group Disclosures Continued

Writing Group Member	Employment	Research Grant	Other Research Support	Speakers' Bureau/ Honoraria	Expert Witness	Ownership Interest	Consultant/ Advisory Board	Other
Philip B. Gorelick	Michigan State University	Bayer*	None	Boehringer Ingelheim*	None	None	New Haven Pharmaceuticals*	None
Steven M. Greenberg	Harvard University	None	None	None	None	None	None	None
Randall T. Higashida	University of California, San Francisco	None	None	None	None	None	None	None
Scott E. Kasner	University of Pennsylvania	W.L. Gore†	None	None	None	None	BMS*	None
Sudha Seshadri	Boston University	None	None	None	None	None	None	None

This table represents the relationships of writing group members that may be perceived as actual or reasonably perceived conflicts of interest as reported on the Disclosure Questionnaire, which all members of the writing group are required to complete and submit. A relationship is considered to be "significant" if (a) the person receives $10 000 or more during any 12-month period, or 5% or more of the person's gross income; or (b) the person owns 5% or more of the voting stock or share of the entity, or owns $10 000 or more of the fair market value of the entity. A relationship is considered to be "modest" if it is less than "significant" under the preceding definition.

*Modest.

†Significant.

Reviewer Disclosures

Reviewer	Employment	Research Grant	Other Research Support	Speakers' Bureau/ Honoraria	Expert Witness	Ownership Interest	Consultant/ Advisory Board	Other
Mitchell S. Elkind	Columbia University	NINDS (NOMAS grant on stroke incidence and risk factors)†	None	None	Merck/ Organon*; BMS-Sanofi*; Hi-Tech*	None	Boehringer-Ingelheim, Inc*; BMS-Pfizer Partnership*; Sanofi-Regeneron*; BioTelemetry/ Cardionet*	American Academy of Neurology (associate editor for the Resident and Fellow Section of *Neurology*, in which capacity I review articles related to dissection and stroke)*; AHA/ASA (board member)*
Rebecca F. Gottesman	Johns Hopkins University	NIH (coinvestigator and collaborator on multiple NIH grants to study small vessel/ cerebrovascular disease)†	None	None	None	None	None	*Neurology* (associate editor)†
Chelsea S. Kidwell	University of Arizona	NIH/NINDS U-01-NS069763 (coinvestigator)†	None	None	None	None	None	None
Joshua Z. Willey	Columbia University	None	None	None	None	None	None	None

This table represents the relationships of reviewers that may be perceived as actual or reasonably perceived conflicts of interest as reported on the Disclosure Questionnaire, which all reviewers are required to complete and submit. A relationship is considered to be "significant" if (a) the person receives $10 000 or more during any 12-month period, or 5% or more of the person's gross income; or (b) the person owns 5% or more of the voting stock or share of the entity, or owns $10 000 or more of the fair market value of the entity. A relationship is considered to be "modest" if it is less than "significant" under the preceding definition.

*Modest.

†Significant.

References

1. Vermeer SE, Longstreth WT Jr, Koudstaal PJ. Silent brain infarcts: a systematic review. *Lancet Neurol*. 2007;6:611–619. doi: 10.1016/S1474-4422(07)70170-9.
2. Leary MC, Saver JL. Annual incidence of first silent stroke in the United States: a preliminary estimate. *Cerebrovasc Dis*. 2003;16:280–285. doi: 71128.
3. Vernooij MW, Ikram MA, Tanghe HL, Vincent AJ, Hofman A, Krestin GP, Niessen WJ, Breteler MM, van der Lugt A. Incidental findings on brain MRI in the general population. *N Engl J Med*. 2007;357:1821–1828. doi: 10.1056/NEJMoa070972.
4. Pantoni L. Cerebral small vessel disease: from pathogenesis and clinical characteristics to therapeutic challenges. *Lancet Neurol*. 2010;9:689–701. doi: 10.1016/S1474-4422(10)70104-6.
5. Greenberg SM, Vernooij MW, Cordonnier C, Viswanathan A, Al-Shahi Salman R, Warach S, Launer LJ, Van Buchem MA, Breteler MM; Microbleed Study Group. Cerebral microbleeds: a guide to detection and interpretation. *Lancet Neurol*. 2009;8:165–174. doi: 10.1016/S1474-4422(09)70013-4.
6. Sacco RL, Kasner SE, Broderick JP, Caplan LR, Connors JJ, Culebras A, Elkind MS, George MG, Hamdan AD, Higashida RT, Hoh BL, Janis LS, Kase CS, Kleindorfer DO, Lee JM, Moseley ME, Peterson ED, Turan TN, Valderrama AL, Vinters HV; on behalf of the American

Heart Association Stroke Council, Council on Cardiovascular Surgery and Anesthesia; Council on Cardiovascular Radiology and Intervention; Council on Cardiovascular and Stroke Nursing; Council on Epidemiology and Prevention; Council on Peripheral Vascular Disease; Council on Nutrition, Physical Activity and Metabolism. An updated definition of stroke for the 21st century: a statement for healthcare professionals from the American Heart Association/American Stroke Association. *Stroke*. 2013;44:2064–2089. doi: 10.1161/STR.0b013e318296aeca.

7. Prins ND, van Dijk EJ, den Heijer T, Vermeer SE, Jolles J, Koudstaal PJ, Hofman A, Breteler MM. Cerebral small-vessel disease and decline in information processing speed, executive function and memory. *Brain*. 2005;128(pt 9):2034–2041. doi: 10.1093/brain/awh553.
8. Longstreth WT Jr, Manolio TA, Arnold A, Burke GL, Bryan N, Jungreis CA, Enright PL, O'Leary D, Fried L. Clinical correlates of white matter findings on cranial magnetic resonance imaging of 3301 elderly people: the Cardiovascular Health Study. *Stroke*. 1996;27:1274–1282.
9. Au R, Massaro JM, Wolf PA, Young ME, Beiser A, Seshadri S, D'Agostino RB, DeCarli C. Association of white matter hyperintensity volume with decreased cognitive functioning: the Framingham Heart Study. *Arch Neurol*. 2006;63:246–250. doi: 10.1001/archneur.63.2.246.
10. Vermeer SE, Hollander M, van Dijk EJ, Hofman A, Koudstaal PJ, Breteler MM; Rotterdam Scan Study. Silent brain infarcts and white matter lesions increase stroke risk in the general population: the Rotterdam Scan Study. *Stroke*. 2003;34:1126–1129. doi: 10.1161/01.STR.0000068408.82115.D2.
11. Vermeer SE, Prins ND, den Heijer T, Hofman A, Koudstaal PJ, Breteler MM. Silent brain infarcts and the risk of dementia and cognitive decline. *N Engl J Med*. 2003;348:1215–1222. doi: 10.1056/NEJMoa022066.
12. Debette S, Beiser A, DeCarli C, Au R, Himali JJ, Kelly-Hayes M, Romero JR, Kase CS, Wolf PA, Seshadri S. Association of MRI markers of vascular brain injury with incident stroke, mild cognitive impairment, dementia, and mortality: the Framingham Offspring Study. *Stroke*. 2010;41:600–606. doi: 10.1161/STROKEAHA.109.570044.
13. Bernick C, Kuller L, Dulberg C, Longstreth WT Jr, Manolio T, Beauchamp N, Price T; Cardiovascular Health Study Collaborative Reseach Group. Silent MRI infarcts and the risk of future stroke: the Cardiovascular Health Study. *Neurology*. 2001;57:1222–1229.
14. Longstreth WT Jr. Brain vascular disease overt and covert. *Stroke*. 2005;36:2062–2063.
15. Gorelick PB, Scuteri A, Black SE, Decarli C, Greenberg SM, Iadecola C, Launer LJ, Laurent S, Lopez OL, Nyenhuis D, Petersen RC, Schneider JA, Tzourio C, Arnett DK, Bennett DA, Chui HC, Higashida RT, Lindquist R, Nilsson PM, Roman GC, Sellke FW, Seshadri S; on behalf of the American Heart Association Stroke Council, Council on Epidemiology and Prevention, Council on Cardiovascular Nursing, Council on Cardiovascular Radiology and Intervention, and Council on Cardiovascular Surgery and Anesthesia. Vascular contributions to cognitive impairment and dementia: a statement for healthcare professionals from the American Heart Association/American Stroke Association. *Stroke*. 2011;42:2672–2713. doi: 10.1161/STR.0b013e3182299496.
16. Wardlaw JM, Smith EE, Biessels GJ, Cordonnier C, Fazekas F, Frayne R, Lindley RI, O'Brien JT, Barkhof F, Benavente OR, Black SE, Brayne C, Breteler M, Chabriat H, Decarli C, de Leeuw FE, Doubal F, Duering M, Fox NC, Greenberg S, Hachinski V, Kilimann I, Mok V, Oostenbrugge Rv, Pantoni L, Speck O, Stephan BC, Teipel S, Viswanathan A, Werring D, Chen C, Smith C, van Buchem M, Norrving B, Gorelick PB, Dichgans M; STandards for ReportIng Vascular changes on nEuroimaging (STRIVE v1). Neuroimaging standards for research into small vessel disease and its contribution to ageing and neurodegeneration. *Lancet Neurol*. 2013;12:822–838. doi: 10.1016/S1474-4422(13)70124-8.
17. Debette S, Markus HS. The clinical importance of white matter hyperintensities on brain magnetic resonance imaging: systematic review and meta-analysis. *BMJ*. 2010;341:c3666.
18. Cordonnier C, Al-Shahi Salman R, Wardlaw J. Spontaneous brain microbleeds: systematic review, subgroup analyses and standards for study design and reporting. *Brain*. 2007;130(pt 8):1988–2003. doi: 10.1093/brain/awl387.
19. Fazekas F, Chawluk JB, Alavi A, Hurtig HI, Zimmerman RA. MR signal abnormalities at 1.5 T in Alzheimer's dementia and normal aging. *AJR Am J Roentgenol*. 1987;149:351–356. doi: 10.2214/ajr.149.2.351.
20. American College of Radiology. ACR-ASNR-SPR practice parameter for the performance and interpretation of magnetic resonance imaging of the brain. http://www.acr.org/~/media/ACR/Documents/PGTS/guidelines/MRI_Brain.pdf. Accessed November 3, 2015.
21. Wardlaw JM, Brindle W, Casado AM, Shuler K, Henderson M, Thomas B, Macfarlane J, Muñoz Maniega S, Lymer K, Morris Z, Pernet C, Nailon W, Ahearn T, Mumuni AN, Mugruza C, McLean J, Chakirova G, Tao YT, Simpson J, Stanfield AC, Johnston H, Parikh J, Royle NA, De Wilde J, Bastin ME, Weir N, Farrall A, Valdes Hernandez MC; SINAPSE Collaborative Group. A systematic review of the utility of 1.5 versus 3 Tesla magnetic resonance brain imaging in clinical practice and research. *Eur Radiol*. 2012;22:2295–2303. doi: 10.1007/s00330-012-2500-8.
22. Hachinski V, Iadecola C, Petersen RC, Breteler MM, Nyenhuis DL, Black SE, Powers WJ, DeCarli C, Merino JG, Kalaria RN, Vinters HV, Holtzman DM, Rosenberg GA, Wallin A, Dichgans M, Marler JR, Leblanc GG. National Institute of Neurological Disorders and Stroke-Canadian Stroke Network vascular cognitive impairment harmonization standards [published correction appears in *Stroke*. 2007;38:1118]. *Stroke*. 2006;37:2220–2241. doi: 10.1161/01.STR.0000237236.88823.47.
23. Potter GM, Marlborough FJ, Wardlaw JM. Wide variation in definition, detection, and description of lacunar lesions on imaging. *Stroke*. 2011;42:359–366. doi: 10.1161/STROKEAHA.110.594754.
24. Zhu YC, Dufouil C, Tzourio C, Chabriat H. Silent brain infarcts: a review of MRI diagnostic criteria. *Stroke*. 2011;42:1140–1145. doi: 10.1161/STROKEAHA.110.600114.
25. Vermeer SE, Koudstaal PJ, Oudkerk M, Hofman A, Breteler MM. Prevalence and risk factors of silent brain infarcts in the population-based Rotterdam Scan Study. *Stroke*. 2002;33:21–25.
26. Moreau F, Patel S, Lauzon ML, McCreary CR, Goyal M, Frayne R, Demchuk AM, Coutts SB, Smith EE. Cavitation after acute symptomatic lacunar stroke depends on time, location, and MRI sequence. *Stroke*. 2012;43:1837–1842. doi: 10.1161/STROKEAHA.111.647859.
27. Bokura H, Kobayashi S, Yamaguchi S. Distinguishing silent lacunar infarction from enlarged Virchow-Robin spaces: a magnetic resonance imaging and pathological study. *J Neurol*. 1998;245:116–122.
28. Potter GM, Doubal FN, Jackson CA, Chappell FM, Sudlow CL, Dennis MS, Wardlaw JM. Counting cavitating lacunes underestimates the burden of lacunar infarction. *Stroke*. 2010;41:267–272. doi: 10.1161/STROKEAHA.109.566307.
29. Smith EE, Schneider JA, Wardlaw JM, Greenberg SM. Cerebral microinfarcts: the invisible lesions. *Lancet Neurol*. 2012;11:272–282. doi: 10.1016/S1474-4422(11)70307-6.
30. Brundel M, de Bresser J, van Dillen JJ, Kappelle LJ, Biessels GJ. Cerebral microinfarcts: a systematic review of neuropathological studies. *J Cereb Blood Flow Metab*. 2012;32:425–436. doi: 10.1038/jcbfm.2011.200.
31. van Dalen JW, Scuric EE, van Veluw SJ, Caan MW, Nederveen AJ, Biessels GJ, van Gool WA, Richard E. Cortical microinfarcts detected in vivo on 3 Tesla MRI: clinical and radiological correlates. *Stroke*. 2015;46:255–257. doi: 10.1161/STROKEAHA.114.007568.
32. DeCarli C, Fletcher E, Ramey V, Harvey D, Jagust WJ. Anatomical mapping of white matter hyperintensities (WMH): exploring the relationships between periventricular WMH, deep WMH, and total WMH burden. *Stroke*. 2005;36:50–55. doi: 10.1161/01.STR.0000150668.58689.f2.
33. Schiffmann R, van der Knaap MS. Invited article: an MRI-based approach to the diagnosis of white matter disorders. *Neurology*. 2009;72:750–759. doi: 10.1212/01.wnl.0000343049.00540.c8.
34. Hesselink JR. Differential diagnostic approach to MR imaging of white matter diseases. *Top Magn Reson Imaging*. 2006;17:243–263. doi: 10.1097/01.rmr.0000248666.91834.af.
35. Wahlund LO, Barkhof F, Fazekas F, Bronge L, Augustin M, Sjögren M, Wallin A, Ader H, Leys D, Pantoni L, Pasquier F, Erkinjuntti T, Scheltens P; European Task Force on Age-Related White Matter Changes. A new rating scale for age-related white matter changes applicable to MRI and CT. *Stroke*. 2001;32:1318–1322.
36. Kapeller P, Barber R, Vermeulen RJ, Adèr H, Scheltens P, Freidl W, Almkvist O, Moretti M, del Ser T, Vaghfeldt P, Enzinger C, Barkhof F, Inzitari D, Erkinjunti T, Schmidt R, Fazekas F; European Task Force of Age Related White Matter Changes. Visual rating of age-related white matter changes on magnetic resonance imaging: scale comparison, interrater agreement, and correlations with quantitative measurements. *Stroke*. 2003;34:441–445.
37. Kobayashi S, Okada K, Koide H, Bokura H, Yamaguchi S. Subcortical silent brain infarction as a risk factor for clinical stroke. *Stroke*. 1997;28:1932–1939.
38. Schmidt R, Fazekas F, Hayn M, Schmidt H, Kapeller P, Roob G, Offenbacher H, Schumacher M, Eber B, Weinrauch V, Kostner GM, Esterbauer H. Risk factors for microangiopathy-related

cerebral damage in the Austrian stroke prevention study. *J Neurol Sci*. 1997;152:15–21.
39. Price TR, Manolio TA, Kronmal RA, Kittner SJ, Yue NC, Robbins J, Anton-Culver H, O'Leary DH. Silent brain infarction on magnetic resonance imaging and neurological abnormalities in community-dwelling older adults: the Cardiovascular Health Study: CHS Collaborative Research Group. *Stroke*. 1997;28:1158–1164.
40. Longstreth WT Jr. Brain abnormalities in the elderly: frequency and predictors in the United States (the Cardiovascular Health Study): Cardiovascular Health Study Collaborative Research Group. *J Neural Transm Suppl*. 1998;53:9–16.
41. Chen X, Wen W, Anstey KJ, Sachdev PS. Prevalence, incidence, and risk factors of lacunar infarcts in a community sample. *Neurology*. 2009;73:266–272. doi: 10.1212/WNL.0b013e3181aa52ea.
42. Longstreth WT Jr, Dulberg C, Manolio TA, Lewis MR, Beauchamp NJ Jr, O'Leary D, Carr J, Furberg CD. Incidence, manifestations, and predictors of brain infarcts defined by serial cranial magnetic resonance imaging in the elderly: the Cardiovascular Health Study. *Stroke*. 2002;33:2376–2382.
43. Vermeer SE, Den Heijer T, Koudstaal PJ, Oudkerk M, Hofman A, Breteler MM; Rotterdam Scan Study. Incidence and risk factors of silent brain infarcts in the population-based Rotterdam Scan Study. *Stroke*. 2003;34:392–396.
44. Gouw AA, van der Flier WM, Fazekas F, van Straaten EC, Pantoni L, Poggesi A, Inzitari D, Erkinjuntti T, Wahlund LO, Waldemar G, Schmidt R, Scheltens P, Barkhof F; LADIS Study Group. Progression of white matter hyperintensities and incidence of new lacunes over a 3-year period: the Leukoaraiosis and Disability study. *Stroke*. 2008;39:1414–1420. doi: 10.1161/STROKEAHA.107.498535.
45. Das RR, Seshadri S, Beiser AS, Kelly-Hayes M, Au R, Himali JJ, Kase CS, Benjamin EJ, Polak JF, O'Donnell CJ, Yoshita M, D'Agostino RB Sr, DeCarli C, Wolf PA. Prevalence and correlates of silent cerebral infarcts in the Framingham Offspring Study. *Stroke*. 2008;39:2929–2935. doi: 10.1161/STROKEAHA.108.516575.
46. Fanning JP, Wong AA, Fraser JF. The epidemiology of silent brain infarction: a systematic review of population-based cohorts. *BMC Med*. 2014;12:119. doi: 10.1186/s12916-014-0119-0.
47. Prabhakaran S, Wright CB, Yoshita M, Delapaz R, Brown T, DeCarli C, Sacco RL. Prevalence and determinants of subclinical brain infarction: the Northern Manhattan Study. *Neurology*. 2008;70:425–430. doi: 10.1212/01.wnl.0000277521.66947.e5.
48. Fornage M, Debette S, Bis JC, Schmidt H, Ikram MA, Dufouil C, Sigurdsson S, Lumley T, DeStefano AL, Fazekas F, Vrooman HA, Shibata DK, Maillard P, Zijdenbos A, Smith AV, Gudnason H, de Boer R, Cushman M, Mazoyer B, Heiss G, Vernooij MW, Enzinger C, Glazer NL, Beiser A, Knopman DS, Cavalieri M, Niessen WJ, Harris TB, Petrovic K, Lopez OL, Au R, Lambert JC, Hofman A, Gottesman RF, Garcia M, Heckbert SR, Atwood LD, Catellier DJ, Uitterlinden AG, Yang Q, Smith NL, Aspelund T, Romero JR, Rice K, Taylor KD, Nalls MA, Rotter JI, Sharrett R, van Duijn CM, Amouyel P, Wolf PA, Gudnason V, van der Lugt A, Boerwinkle E, Psaty BM, Seshadri S, Tzourio C, Breteler MM, Mosley TH, Schmidt R, Longstreth WT, DeCarli C, Launer LJ. Genome-wide association studies of cerebral white matter lesion burden: the CHARGE consortium. *Ann Neurol*. 2011;69:928–939. doi: 10.1002/ana.22403.
49. Atwood LD, Wolf PA, Heard-Costa NL, Massaro JM, Beiser A, D'Agostino RB, DeCarli C. Genetic variation in white matter hyperintensity volume in the Framingham study. *Stroke*. 2004;35:1609–1613. doi: 10.1161/01.STR.0000129643.77045.10.
50. Verhaaren BF, Debette S, Bis JC, Smith JA, Ikram MK, Adams HH, Beecham AH, Rajan KB, Lopez LM, Barral S, van Buchem MA, van der Grond J, Smith AV, Hegenscheid K, Aggarwal NT, de Andrade M, Atkinson EJ, Beekman M, Beiser AS, Blanton SH, Boerwinkle E, Brickman AM, Bryan RN, Chauhan G, Chen CP, Chouraki V, de Craen AJ, Crivello F, Deary IJ, Deelen J, De Jager PL, Dufouil C, Elkind MS, Evans DA, Freudenberger P, Gottesman RF, Guðnason V, Habes M, Heckbert SR, Heiss G, Hilal S, Hofer E, Hofman A, Ibrahim-Verbaas CA, Knopman DS, Lewis CE, Liao J, Liewald DC, Luciano M, van der Lugt A, Martinez OO, Mayeux R, Mazoyer B, Nalls M, Nauck M, Niessen WJ, Oostra BA, Psaty BM, Rice KM, Rotter JI, von Sarnowski B, Schmidt H, Schreiner PJ, Schuur M, Sidney SS, Sigurdsson S, Slagboom PE, Stott DJ, van Swieten JC, Teumer A, Töglhofer AM, Traylor M, Trompet S, Turner ST, Tzourio C, Uh HW, Uitterlinden AG, Vernooij MW, Wang JJ, Wong TY, Wardlaw JM, Windham BG, Wittfeld K, Wolf C, Wright CB, Yang Q, Zhao W, Zijdenbos A, Jukema JW, Sacco RL, Kardia SL, Amouyel P, Mosley TH, Longstreth WT Jr, DeCarli CC, van Duijn CM, Schmidt R, Launer LJ, Grabe HJ, Seshadri SS, Ikram MA, Fornage M. Multiethnic genome-wide association study of cerebral white matter hyperintensities on MRI. *Circ Cardiovasc Genet*. 2015;8:398–409. doi: 10.1161/CIRCGENETICS.114.000858.
51. Allan CL, Zsoldos E, Filippini N, Sexton CE, Topiwala A, Valkanova V, Singh-Manoux A, Tabák AG, Shipley MJ, Mackay C, Ebmeier KP, Kivimäki M. Lifetime hypertension as a predictor of brain structure in older adults: cohort study with a 28-year follow-up. *Br J Psychiatry*. 2015;206:308–315. doi: 10.1192/bjp.bp.114.153536.
52. Swan GE, DeCarli C, Miller BL, Reed T, Wolf PA, Jack LM, Carmelli D. Association of midlife blood pressure to late-life cognitive decline and brain morphology. *Neurology*. 1998;51:986–993.
53. Pavese N, Canapicchi R, Nuti A, Bibbiani F, Lucetti C, Collavoli P, Bonuccelli U. White matter MRI hyperintensities in a hundred and twenty-nine consecutive migraine patients. *Cephalalgia*. 1994;14:342–345.
54. Hamedani AG, Rose KM, Peterlin BL, Mosley TH, Coker LH, Jack CR, Knopman DS, Alonso A, Gottesman RF. Migraine and white matter hyperintensities: the ARIC MRI study. *Neurology*. 2013;81:1308–1313. doi: 10.1212/WNL.0b013e3182a8235b.
55. Jorm AF, Anstey KJ, Christensen H, de Plater G, Kumar R, Wen W, Sachdev P. MRI hyperintensities and depressive symptoms in a community sample of individuals 60-64 years old. *Am J Psychiatry*. 2005;162:699–705. doi: 10.1176/appi.ajp.162.4.699.
56. Breeze JL, Hesdorffer DC, Hong X, Frazier JA, Renshaw PF. Clinical significance of brain white matter hyperintensities in young adults with psychiatric illness. *Harv Rev Psychiatry*. 2003;11:269–283.
57. Hopkins RO, Beck CJ, Burnett DL, Weaver LK, Victoroff J, Bigler ED. Prevalence of white matter hyperintensities in a young healthy population. *J Neuroimaging*. 2006;16:243–251.
58. DeCarli C, Miller BL, Swan GE, Reed T, Wolf PA, Garner J, Jack L, Carmelli D. Predictors of brain morphology for the men of the NHLBI twin study. *Stroke*. 1999;30:529–536.
59. Dufouil C, de Kersaint-Gilly A, Besançon V, Levy C, Auffray E, Brunnereau L, Alpérovitch A, Tzourio C. Longitudinal study of blood pressure and white matter hyperintensities: the EVA MRI cohort. *Neurology*. 2001;56:921–926.
60. Mosley TH Jr, Knopman DS, Catellier DJ, Bryan N, Hutchinson RG, Grothues CA, Folsom AR, Cooper LS, Burke GL, Liao D, Szklo M. Cerebral MRI findings and cognitive functioning: the Atherosclerosis Risk in Communities study. *Neurology*. 2005;64:2056–2062. doi: 10.1212/01.WNL.0000165985.97397.88.
61. Brickman AM, Schupf N, Manly JJ, Luchsinger JA, Andrews H, Tang MX, Reitz C, Small SA, Mayeux R, DeCarli C, Brown TR. Brain morphology in older African Americans, Caribbean Hispanics, and whites from northern Manhattan. *Arch Neurol*. 2008;65:1053–1061. doi: 10.1001/archneur.65.8.1053.
62. Del Brutto OH, Mera RM, Del Brutto VJ, Zambrano M, Lama J. White matter hyperintensities of presumed vascular origin: a population-based study in rural Ecuador (the Atahualpa Project). *Int J Stroke*. 2015;10:372–375. doi: 10.1111/ijs.12417.
63. Liao D, Cooper L, Cai J, Toole J, Bryan N, Burke G, Shahar E, Nieto J, Mosley T, Heiss G. The prevalence and severity of white matter lesions, their relationship with age, ethnicity, gender, and cardiovascular disease risk factors: the ARIC Study. *Neuroepidemiology*. 1997;16:149–162.
64. Scheltens P, Barkhof F, Valk J, Algra PR, van der Hoop RG, Nauta J, Wolters EC. White matter lesions on magnetic resonance imaging in clinically diagnosed Alzheimer's disease: evidence for heterogeneity. *Brain*. 1992;115(pt 3):735–748.
65. Wardlaw JM, Ferguson KJ, Graham C. White matter hyperintensities and rating scales-observer reliability varies with lesion load. *J Neurol*. 2004;251:584–590. doi: 10.1007/s00415-004-0371-x.
66. Sandeman EM, Hernandez Mdel C, Morris Z, Bastin ME, Murray C, Gow AJ, Corley J, Henderson R, Deary IJ, Starr JM, Wardlaw JM. Incidental findings on brain MR imaging in older community-dwelling subjects are common but serious medical consequences are rare: a cohort study. *PLoS One*. 2013;8:e71467. doi: 10.1371/journal.pone.0071467.
67. Fazekas F, Schmidt R, Kleinert R, Kapeller P, Roob G, Flooh E. The spectrum of age-associated brain abnormalities: their measurement and histopathological correlates. *J Neural Transm Suppl*. 1998;53:31–39.
68. Söderlund H, Nyberg L, Adolfsson R, Nilsson LG, Launer LJ. High prevalence of white matter hyperintensities in normal aging: relation to blood pressure and cognition. *Cortex*. 2003;39:1093–1105.
69. DeCarli C, Murphy DG, Tranh M, Grady CL, Haxby JV, Gillette JA, Salerno JA, Gonzales-Aviles A, Horwitz B, Rapoport SI, Schapiro MB.

The effect of white matter hyperintensity volume on brain structure, cognitive performance, and cerebral metabolism of glucose in 51 healthy adults. *Neurology*. 1995;45:2077–2084.
70. Jeerakathil T, Wolf PA, Beiser A, Massaro J, Seshadri S, D'Agostino RB, DeCarli C. Stroke risk profile predicts white matter hyperintensity volume: the Framingham study. *Stroke*. 2004;35:1857–1861. doi: 10.1161/01.STR.0000135226.53499.85.
71. Smith EE, Egorova S, Blacker D, Killiany RJ, Muzikansky A, Dickerson BC, Tanzi RE, Albert MS, Greenberg SM, Guttmann CR. Magnetic resonance imaging white matter hyperintensities and brain volume in the prediction of mild cognitive impairment and dementia. *Arch Neurol*. 2008;65:94–100. doi: 10.1001/archneurol.2007.23.
72. Rost NS, Rahman RM, Biffi A, Smith EE, Kanakis A, Fitzpatrick K, Lima F, Worrall BB, Meschia JF, Brown RD Jr, Brott TG, Sorensen AG, Greenberg SM, Furie KL, Rosand J. White matter hyperintensity volume is increased in small vessel stroke subtypes. *Neurology*. 2010;75:1670–1677. doi: 10.1212/WNL.0b013e3181fc279a.
73. Schmidt R, Fazekas F, Kleinert G, Offenbacher H, Gindl K, Payer F, Freidl W, Niederkorn K, Lechner H. Magnetic resonance imaging signal hyperintensities in the deep and subcortical white matter: a comparative study between stroke patients and normal volunteers. *Arch Neurol*. 1992;49:825–827.
74. Schmidt R, Schmidt H, Haybaeck J, Loitfelder M, Weis S, Cavalieri M, Seiler S, Enzinger C, Ropele S, Erkinjuntti T, Pantoni L, Scheltens P, Fazekas F, Jellinger K. Heterogeneity in age-related white matter changes. *Acta Neuropathol*. 2011;122:171–185. doi: 10.1007/s00401-011-0851-x.
75. Smith EE, O'Donnell M, Dagenais G, Lear SA, Wielgosz A, Sharma M, Poirier P, Stotts G, Black SE, Strother S, Noseworthy MD, Benavente O, Modi J, Goyal M, Batool S, Sanchez K, Hill V, McCreary CR, Frayne R, Islam S, DeJesus J, Rangarajan S, Teo K, Yusuf S; PURE Investigators. Early cerebral small vessel disease and brain volume, cognition, and gait. *Ann Neurol*. 2015;77:251–261. doi: 10.1002/ana.24320.
76. de Leeuw FE, de Groot JC, Oudkerk M, Witteman JC, Hofman A, van Gijn J, Breteler MM. A follow-up study of blood pressure and cerebral white matter lesions. *Ann Neurol*. 1999;46:827–833.
77. Roob G, Schmidt R, Kapeller P, Lechner A, Hartung HP, Fazekas F. MRI evidence of past cerebral microbleeds in a healthy elderly population. *Neurology*. 1999;52:991–994.
78. Jeerakathil T, Wolf PA, Beiser A, Hald JK, Au R, Kase CS, Massaro JM, DeCarli C. Cerebral microbleeds: prevalence and associations with cardiovascular risk factors in the Framingham Study. *Stroke*. 2004;35:1831–1835. doi: 10.1161/01.STR.0000131809.35202.1b.
79. Kuller LH, Longstreth WT Jr, Arnold AM, Bernick C, Bryan RN, Beauchamp NJ Jr; Cardiovascular Health Study Collaborative Research Group. White matter hyperintensity on cranial magnetic resonance imaging: a predictor of stroke. *Stroke*. 2004;35:1821–1825. doi: 10.1161/01.STR.0000132193.35955.69.
80. Yakushiji Y, Nishiyama M, Yakushiji S, Hirotsu T, Uchino A, Nakajima J, Eriguchi M, Nanri Y, Hara M, Horikawa E, Kuroda Y. Brain microbleeds and global cognitive function in adults without neurological disorder. *Stroke*. 2008;39:3323–3328. doi: 10.1161/STROKEAHA.108.516112.
81. Sveinbjornsdottir S, Sigurdsson S, Aspelund T, Kjartansson O, Eiriksdottir G, Valtysdottir B, Lopez OL, van Buchem MA, Jonsson PV, Gudnason V, Launer LJ. Cerebral microbleeds in the population based AGES-Reykjavik study: prevalence and location. *J Neurol Neurosurg Psychiatry*. 2008;79:1002–1006. doi: 10.1136/jnnp.2007.121913.
82. Liu PF, Cui YZ, Na J, Gao PY. Cerebral microbleeds: prevalence, distribution and risk factors in northeast population without preceding large-area stroke. *Chin Med J (Engl)*. 2010;123:286–290.
83. van Es AC, van der Grond J, de Craen AJ, Westendorp RG, Bollen EL, Blauw GJ, Greenberg SM, van Buchem MA; PROSPER Study Group. Cerebral microbleeds and cognitive functioning in the PROSPER study. *Neurology*. 2011;77:1446–1452. doi: 10.1212/WNL.0b013e318232ab1d.
84. Romero JR, Preis SR, Beiser A, DeCarli C, Viswanathan A, Martinez-Ramirez S, Kase CS, Wolf PA, Seshadri S. Risk factors, stroke prevention treatments, and prevalence of cerebral microbleeds in the Framingham Heart Study. *Stroke*. 2014;45:1492–1494. doi: 10.1161/STROKEAHA.114.004130.
85. Koennecke HC. Cerebral microbleeds on MRI: prevalence, associations, and potential clinical implications. *Neurology*. 2006;66:165–171. doi: 10.1212/01.wnl.0000194266.55694.1e.
86. Wiegman AF, Meier IB, Schupf N, Manly JJ, Guzman VA, Narkhede A, Stern Y, Martinez-Ramirez S, Viswanathan A, Luchsinger JA, Greenberg SM, Mayeux R, Brickman AM. Cerebral microbleeds in a multiethnic elderly community: demographic and clinical correlates. *J Neurol Sci*. 2014;345:125–130. doi: 10.1016/j.jns.2014.07.024.
87. Linn J, Halpin A, Demaerel P, Ruhland J, Giese AD, Dichgans M, van Buchem MA, Bruckmann H, Greenberg SM. Prevalence of superficial siderosis in patients with cerebral amyloid angiopathy. *Neurology*. 2010;74:1346–1350. doi: 10.1212/WNL.0b013e3181dad605.
88. Martinez-Ramirez S, Romero JR, Shoamanesh A, McKee AC, Van Etten E, Pontes-Neto O, Macklin EA, Ayres A, Auriel E, Himali JJ, Beiser AS, DeCarli C, Stein TD, Alvarez VE, Frosch MP, Rosand J, Greenberg SM, Gurol ME, Seshadri S, Viswanathan A. Diagnostic value of lobar microbleeds in individuals without intracerebral hemorrhage. *Alzheimers Dement*. 2015;11:1480–1488. doi: 10.1016/j.jalz.2015.04.009.
89. Yue NC, Longstreth WT Jr, Elster AD, Jungreis CA, O'Leary DH, Poirier VC. Clinically serious abnormalities found incidentally at MR imaging of the brain: data from the Cardiovascular Health Study. *Radiology*. 1997;202:41–46. doi: 10.1148/radiology.202.1.8988190.
90. Kernan WN, Ovbiagele B, Black HR, Bravata DM, Chimowitz MI, Ezekowitz MD, Fang MC, Fisher M, Furie KL, Heck DV, Johnston SC, Kasner SE, Kittner SJ, Mitchell PH, Rich MW, Richardson D, Schwamm LH, Wilson JA; on behalf of the American Heart Association Stroke Council, Council on Cardiovascular and Stroke Nursing, Council on Clinical Cardiology, and Council on Peripheral Vascular Disease. Guidelines for the prevention of stroke in patients with stroke and transient ischemic attack: a guideline for healthcare professionals from the American Heart Association/American Stroke Association [published correction appears in *Stroke*. 2015;46:e54]. *Stroke*. 2014;45:2160–2236. doi: 10.1161/STR.0000000000000024.
91. Meschia JF, Bushnell C, Boden-Albala B, Braun LT, Bravata DM, Chaturvedi S, Creager MA, Eckel RH, Elkind MS, Fornage M, Goldstein LB, Greenberg SM, Horvath SE, Iadecola C, Jauch EC, Moore WS, Wilson JA; on behalf of the American Heart Association Stroke Council; Council on Cardiovascular and Stroke Nursing; Council on Clinical Cardiology; Council on Functional Genomics and Translational Biology; Council on Hypertension. Guidelines for the primary prevention of stroke: a statement for healthcare professionals from the American Heart Association/American Stroke Association. *Stroke*. 2014;45:3754–3832. doi: 10.1161/STR.0000000000000046.
92. Adams HP Jr, Bendixen BH, Kappelle LJ, Biller J, Love BB, Gordon DL, Marsh EE 3rd. Classification of subtype of acute ischemic stroke: definitions for use in a multicenter clinical trial: TOAST: Trial of Org 10172 in Acute Stroke Treatment. *Stroke*. 1993;24:35–41.
93. Ay H, Benner T, Arsava EM, Furie KL, Singhal AB, Jensen MB, Ayata C, Towfighi A, Smith EE, Chong JY, Koroshetz WJ, Sorensen AG. A computerized algorithm for etiologic classification of ischemic stroke: the Causative Classification of Stroke System. *Stroke*. 2007;38:2979–2984. doi: 10.1161/STROKEAHA.107.490896.
94. Jauch EC, Saver JL, Adams HP Jr, Bruno A, Connors JJ, Demaerschalk BM, Khatri P, McMullan PW Jr, Qureshi AI, Rosenfield K, Scott PA, Summers DR, Wang DZ, Wintermark M, Yonas H; on behalf of the American Heart Association Stroke Council; Council on Cardiovascular Nursing; Council on Peripheral Vascular Disease; Council on Clinical Cardiology. Guidelines for the early management of patients with acute ischemic stroke: a guideline for healthcare professionals from the American Heart Association/American Stroke Association. *Stroke*. 2013;44:870–947. doi: 10.1161/STR.0b013e318284056a.
95. Lip GY, Nieuwlaat R, Pisters R, Lane DA, Crijns HJ. Refining clinical risk stratification for predicting stroke and thromboembolism in atrial fibrillation using a novel risk factor-based approach: the Euro Heart Survey on Atrial Fibrillation. *Chest*. 2010;137:263–272.
96. Feinberg WM, Seeger JF, Carmody RF, Anderson DC, Hart RG, Pearce LA. Epidemiologic features of asymptomatic cerebral infarction in patients with nonvalvular atrial fibrillation. *Arch Intern Med*. 1990;150:2340–2344.
97. Silent brain infarction in nonrheumatic atrial fibrillation: EAFT Study Group: European Atrial Fibrillation Trial. *Neurology*. 1996;46:159–165.
98. Ezekowitz MD, James KE, Nazarian SM, Davenport J, Broderick JP, Gupta SR, Thadani V, Meyer ML, Bridgers SL. Silent cerebral infarction in patients with nonrheumatic atrial fibrillation: the Veterans Affairs Stroke Prevention in Nonrheumatic Atrial Fibrillation Investigators. *Circulation*. 1995;92:2178–2182.
99. Favilla CG, Ingala E, Jara J, Fessler E, Cucchiara B, Messé SR, Mullen MT, Prasad A, Siegler J, Hutchinson MD, Kasner SE. Predictors of finding occult atrial fibrillation after cryptogenic stroke. *Stroke*. 2015;46:1210–1215. doi: 10.1161/STROKEAHA.114.007763.

100. Brott T, Tomsick T, Feinberg W, Johnson C, Biller J, Broderick J, Kelly M, Frey J, Schwartz S, Blum C, Nelson JJ, Chambless L, Toole J; Asymptomatic Carotid Atherosclerosis Study Investigators. Baseline silent cerebral infarction in the Asymptomatic Carotid Atherosclerosis Study. *Stroke*. 1994;25:1122–1129.
101. Cao P, Zannetti S, Giordano G, De Rango P, Parlani G, Caputo N. Cerebral tomographic findings in patients undergoing carotid endarterectomy for asymptomatic carotid stenosis: short-term and long-term implications. *J Vasc Surg*. 1999;29:995–1005.
102. Hougaku H, Matsumoto M, Handa N, Maeda H, Itoh T, Tsukamoto Y, Kamada T. Asymptomatic carotid lesions and silent cerebral infarction. *Stroke*. 1994;25:566–570.
103. Jayasooriya G, Thapar A, Shalhoub J, Davies AH. Silent cerebral events in asymptomatic carotid stenosis. *J Vasc Surg*. 2011;54:227–236. doi: 10.1016/j.jvs.2011.01.037.
104. Federico A, Di Donato I, Bianchi S, Di Palma C, Taglia I, Dotti MT. Hereditary cerebral small vessel diseases: a review. *J Neurol Sci*. 2012;322:25–30. doi: 10.1016/j.jns.2012.07.041.
105. Kilarski LL, Rutten-Jacobs LC, Bevan S, Baker R, Hassan A, Hughes DA, Markus HS; UK Young Lacunar Stroke DNA Study. Prevalence of CADASIL and Fabry disease in a cohort of MRI defined younger onset lacunar stroke. *PLoS One*. 2015;10:e0136352. doi: 10.1371/journal.pone.0136352.
106. Chabriat H, Joutel A, Dichgans M, Tournier-Lasserve E, Bousser MG. Cadasil. *Lancet Neurol*. 2009;8:643–653. doi: 10.1016/S1474-4422(09)70127-9.
107. de Leeuw FE, de Groot JC, Oudkerk M, Kors JA, Hofman A, van Gijn J, Breteler MM. Atrial fibrillation and the risk of cerebral white matter lesions. *Neurology*. 2000;54:1795–1801.
108. Windham BG, Deere B, Griswold ME, Wang W, Bezerra DC, Shibata D, Butler K, Knopman D, Gottesman RF, Heiss G, Mosley TH Jr. Small brain lesions and incident stroke and mortality: a cohort study. *Ann Intern Med*. 2015;163:22–31. doi: 10.7326/M14-2057.
109. Liao SQ, Li JC, Zhang M, Wang YJ, Li BH, Yin YW, Liu Y, Gao CY, Zhang LL. The association between leukoaraiosis and carotid atherosclerosis: a systematic review and meta-analysis. *Int J Neurosci*. 2015;125:493–500. doi: 10.3109/00207454.2014.949703.
110. Poels MM, Vernooij MW, Ikram MA, Hofman A, Krestin GP, van der Lugt A, Breteler MM. Prevalence and risk factors of cerebral microbleeds: an update of the Rotterdam scan study. *Stroke*. 2010;41(suppl):S103–S106. doi: 10.1161/STROKEAHA.110.595181.
111. Knudsen KA, Rosand J, Karluk D, Greenberg SM. Clinical diagnosis of cerebral amyloid angiopathy: validation of the Boston criteria. *Neurology*. 2001;56:537–539.
112. Hemphill JC 3rd, Greenberg SM, Anderson CS, Becker K, Bendok BR, Cushman M, Fung GL, Goldstein JN, Macdonald RL, Mitchell PH, Scott PA, Selim MH, Woo D; on behalf of the American Heart Association Stroke Council; Council on Cardiovascular and Stroke Nursing; Council on Clinical Cardiology. Guidelines for the management of spontaneous intracerebral hemorrhage: a guideline for healthcare professionals from the American Heart Association/American Stroke Association. *Stroke*. 2015;46:2032–2060. doi: 10.1161/STR.0000000000000069.
113. Hasegawa Y, Yamaguchi T, Omae T, Woodward M, Chalmers J; PROGRESS CT Substudy Investigators. Effects of perindopril-based blood pressure lowering and of patient characteristics on the progression of silent brain infarct: the Perindopril Protection against Recurrent Stroke Study (PROGRESS) CT Substudy in Japan [published correction appears in *Hypertens Res*. 2004;27:447]. *Hypertens Res*. 2004;27:147–156.
114. Weber R, Weimar C, Wanke I, Möller-Hartmann C, Gizewski ER, Blatchford J, Hermansson K, Demchuk AM, Forsting M, Sacco RL, Saver JL, Warach S, Diener HC, Diehl A; PRoFESS Imaging Substudy Group. Risk of recurrent stroke in patients with silent brain infarction in the Prevention Regimen for Effectively Avoiding Second Strokes (PRoFESS) imaging substudy. *Stroke*. 2012;43:350–355. doi: 10.1161/STROKEAHA.111.631739.
115. Nelson M, Reid C, Beilin L, Donnan G, Johnston C, Krum H, Storey E, Tonkin A, McNeil J; Aspirin in Reducing Events in the Elderly (ASPREE) Study Group. Rationale for a trial of low-dose aspirin for the primary prevention of major adverse cardiovascular events and vascular dementia in the elderly: Aspirin in Reducing Events in the Elderly (ASPREE). *Drugs Aging*. 2003;20:897–903.
116. Reid CM, Storey E, Wong TY, Woods R, Tonkin A, Wang JJ, Kam A, Janke A, Essex R, Abhayaratna WP, Budge MM; ASPREE Study Group. Aspirin for the prevention of cognitive decline in the elderly: rationale and design of a neuro-vascular imaging study (ENVIS-ion). *BMC Neurol*. 2012;12:3. doi: 10.1186/1471-2377-12-3.
117. Paraskevas KI, Spence JD, Veith FJ, Nicolaides AN. Identifying which patients with asymptomatic carotid stenosis could benefit from intervention. *Stroke*. 2014;45:3720–3724. doi: 10.1161/STROKEAHA.114.006912.
118. Goff DC Jr, Lloyd-Jones DM, Bennett G, Coady S, D'Agostino RB, Gibbons R, Greenland P, Lackland DT, Levy D, O'Donnell CJ, Robinson JG, Schwartz JS, Shero ST, Smith SC Jr, Sorlie P, Stone NJ, Wilson PW, Jordan HS, Nevo L, Wnek J, Anderson JL, Halperin JL, Albert NM, Bozkurt B, Brindis RG, Curtis LH, DeMets D, Hochman JS, Kovacs RJ, Ohman EM, Pressler SJ, Sellke FW, Shen WK, Smith SC Jr, Tomaselli GF. 2013 ACC/AHA guideline on the assessment of cardiovascular risk: a report of the American College of Cardiology/American Heart Association Task Force on Practice Guidelines [published correction appears in *Circulation*. 2014;129(suppl 2):S74–S75]. *Circulation*. 2014;129(suppl 2):S49–S73. doi: 10.1161/01.cir.0000437741.48606.98.
119. Stone NJ, Robinson JG, Lichtenstein AH, Bairey Merz CN, Blum CB, Eckel RH, Goldberg AC, Gordon D, Levy D, Lloyd-Jones DM, McBride P, Schwartz JS, Shero ST, Smith SC Jr, Watson K, Wilson PW, Eddleman KM, Jarrett NM, LaBresh K, Nevo L, Wnek J, Anderson JL, Halperin JL, Albert NM, Bozkurt B, Brindis RG, Curtis LH, DeMets D, Hochman JS, Kovacs RJ, Ohman EM, Pressler SJ, Sellke FW, Shen WK, Smith SC Jr, Tomaselli GF. 2013 ACC/AHA guideline on the treatment of blood cholesterol to reduce atherosclerotic cardiovascular risk in adults: a report of the American College of Cardiology/American Heart Association Task Force on Practice Guidelines [published corrections appear in *Circulation*. 2014;129(suppl 2):S46–S48 and *Circulation*. 2015;132:e396]. *Circulation*. 2014;129:S1–S45. doi: 10.1161/01.cir.0000437738.63853.7a.
120. Iadecola C. The pathobiology of vascular dementia. *Neuron*. 2013;80:844–866. doi: 10.1016/j.neuron.2013.10.008.
121. Wardlaw JM, Smith C, Dichgans M. Mechanisms of sporadic cerebral small vessel disease: insights from neuroimaging [published correction appears in *Lancet Neurol*. 2013;12:532]. *Lancet Neurol*. 2013;12:483–497. doi: 10.1016/S1474-4422(13)70060-7.
122. American Heart Association/American College of Cardiology. CV Risk Calculator. http://my.americanheart.org/cvriskcalculator. Accessed November 9, 2016.
123. Dufouil C, Chalmers J, Coskun O, Besançon V, Bousser MG, Guillon P, MacMahon S, Mazoyer B, Neal B, Woodward M, Tzourio-Mazoyer N, Tzourio C; PROGRESS MRI Substudy Investigators. Effects of blood pressure lowering on cerebral white matter hyperintensities in patients with stroke: the PROGRESS (Perindopril Protection Against Recurrent Stroke Study) Magnetic Resonance Imaging Substudy. *Circulation*. 2005;112:1644–1650. doi: 10.1161/CIRCULATIONAHA.104.501163.
124. Weber R, Weimar C, Blatchford J, Hermansson K, Wanke I, Möller-Hartmann C, Gizewski ER, Forsting M, Demchuk AM, Sacco RL, Saver JL, Warach S, Diener HC, Diehl A; PRoFESS Imaging Substudy Group. Telmisartan on top of antihypertensive treatment does not prevent progression of cerebral white matter lesions in the Prevention Regimen for Effectively Avoiding Second Strokes (PRoFESS) MRI substudy. *Stroke*. 2012;43:2336–2342. doi: 10.1161/STROKEAHA.111.648576.
125. Xiong Y, Wong A, Cavalieri M, Schmidt R, Chu WW, Liu X, Wong KS, Mok V. Prestroke statins, progression of white matter hyperintensities, and cognitive decline in stroke patients with confluent white matter hyperintensities. *Neurotherapeutics*. 2014;11:606–611. doi: 10.1007/s13311-014-0270-5.
126. ten Dam VH, van den Heuvel DM, van Buchem MA, Westendorp RG, Bollen EL, Ford I, de Craen AJ, Blauw GJ; PROSPER Study Group. Effect of pravastatin on cerebral infarcts and white matter lesions. *Neurology*. 2005;64:1807–1809. doi: 10.1212/01.WNL.0000161844.00797.73.
127. Mok VC, Lam WW, Fan YH, Wong A, Ng PW, Tsoi TH, Yeung V, Wong KS. Effects of statins on the progression of cerebral white matter lesion: post hoc analysis of the ROCAS (Regression of Cerebral Artery Stenosis) study. *J Neurol*. 2009;256:750–757. doi: 10.1007/s00415-009-5008-7.
128. Launer LJ, Miller ME, Williamson JD, Lazar RM, Gerstein HC, Murray AM, Sullivan M, Horowitz KR, Ding J, Marcovina S, Lovato LC, Lovato J, Margolis KL, O'Connor P, Lipkin EW, Hirsch J, Coker L, Maldjian J, Sunshine JL, Truwit C, Davatzikos C, Bryan RN; ACCORD MIND Investigators. Effects of intensive glucose lowering on brain structure and function in people with type 2 diabetes (ACCORD MIND): a randomised open-label substudy. *Lancet Neurol*. 2011;10:969–977. doi: 10.1016/S1474-4422(11)70188-0.

129. Cavalieri M, Schmidt R, Chen C, Mok V, de Freitas GR, Song S, Yi Q, Ropele S, Grazer A, Homayoon N, Enzinger C, Loh K, Wong KS, Wong A, Xiong Y, Chang HM, Wong MC, Fazekas F, Eikelboom JW, Hankey GJ; VITATOPS Trial Study Group. B vitamins and magnetic resonance imaging-detected ischemic brain lesions in patients with recent transient ischemic attack or stroke: the VITAmins TO Prevent Stroke (VITATOPS) MRI-substudy. *Stroke*. 2012;43:3266–3270. doi: 10.1161/STROKEAHA.112.665703.
130. Richard E, Gouw AA, Scheltens P, van Gool WA. Vascular care in patients with Alzheimer disease with cerebrovascular lesions slows progression of white matter lesions on MRI: the Evaluation of Vascular Care in Alzheimer's Disease (EVA) study. *Stroke*. 2010;41:554–556. doi: 10.1161/STROKEAHA.109.571281.
131. Gorter JW. Major bleeding during anticoagulation after cerebral ischemia: patterns and risk factors: Stroke Prevention In Reversible Ischemia Trial (SPIRIT): European Atrial Fibrillation Trial (EAFT) study groups. *Neurology*. 1999;53:1319–1327.
132. Richard E, Kuiper R, Dijkgraaf MG, Van Gool WA; Evaluation of Vascular care in Alzheimer's disease. Vascular care in patients with Alzheimer's disease with cerebrovascular lesions: a randomized clinical trial. *J Am Geriatr Soc*. 2009;57:797–805.
133. Thoonsen H, Richard E, Bentham P, Gray R, van Geloven N, De Haan RJ, Van Gool WA, Nederkoorn PJ. Aspirin in Alzheimer's disease: increased risk of intracerebral hemorrhage: cause for concern? *Stroke*. 2010;41:2690–2692. doi: 10.1161/STROKEAHA.109.576975.
134. Zheng JJ, Delbaere K, Close JC, Sachdev PS, Lord SR. Impact of white matter lesions on physical functioning and fall risk in older people: a systematic review. *Stroke*. 2011;42:2086–2090. doi: 10.1161/STROKEAHA.110.610360.
135. Furie KL, Goldstein LB, Albers GW, Khatri P, Neyens R, Turakhia MP, Turan TN, Wood KA; on behalf of the American Heart Association Stroke Council; Council on Quality of Care and Outcomes Research; Council on Cardiovascular Nursing; Council on Clinical Cardiology; Council on Peripheral Vascular Disease. Oral antithrombotic agents for the prevention of stroke in nonvalvular atrial fibrillation: a science advisory for healthcare professionals from the American Heart Association/American Stroke Association [published corrections appear in *Stroke*. 2012;43:e181 and *Stroke*. 2013;44:e20]. *Stroke*. 2012;43:3442–3453. doi: 10.1161/STR.0b013e318266722a.
136. Hart RG, Pearce LA, Aguilar MI. Meta-analysis: antithrombotic therapy to prevent stroke in patients who have nonvalvular atrial fibrillation. *Ann Intern Med*. 2007;146:857–867.
137. Hylek EM, Go AS, Chang Y, Jensvold NG, Henault LE, Selby JV, Singer DE. Effect of intensity of oral anticoagulation on stroke severity and mortality in atrial fibrillation. *N Engl J Med*. 2003;349:1019–1026. doi: 10.1056/NEJMoa022913.
138. Andersen KK, Olsen TS. Reduced poststroke mortality in patients with stroke and atrial fibrillation treated with anticoagulants: results from a Danish quality-control registry of 22,179 patients with ischemic stroke. *Stroke*. 2007;38:259–263. doi: 10.1161/01.STR.0000254622.52483.03.
139. McGrath ER, Kapral MK, Fang J, Eikelboom JW, Conghaile Aó, O'Conghaile A, Canavan M, O'Donnell MJ; Investigators of the Ontario Stroke Registry. Association of atrial fibrillation with mortality and disability after ischemic stroke [published corrections appear in *Neurology*. 2013;81:825–832 and *Neurology*. 2016;86:492]. *Neurology*. 2013;81:825–832. doi: 10.1212/WNL.0b013e3182a2cc15.
140. Ruff CT, Giugliano RP, Braunwald E, Hoffman EB, Deenadayalu N, Ezekowitz MD, Camm AJ, Weitz JI, Lewis BS, Parkhomenko A, Yamashita T, Antman EM. Comparison of the efficacy and safety of new oral anticoagulants with warfarin in patients with atrial fibrillation: a meta-analysis of randomised trials. *Lancet*. 2014;383:955–962. doi: 10.1016/S0140-6736(13)62343-0.
141. Fang MC, Go AS, Chang Y, Hylek EM, Henault LE, Jensvold NG, Singer DE. Death and disability from warfarin-associated intracranial and extracranial hemorrhages. *Am J Med*. 2007;120:700–705. doi: 10.1016/j.amjmed.2006.07.034.
142. Kaatz S, Kouides PA, Garcia DA, Spyropolous AC, Crowther M, Douketis JD, Chan AK, James A, Moll S, Ortel TL, Van Cott EM, Ansell J. Guidance on the emergent reversal of oral thrombin and factor Xa inhibitors [published correction appears in *Am J Hematol*. 2012;87:748]. *Am J Hematol*. 2012;87(suppl 1):S141–S145. doi: 10.1002/ajh.23202.
143. Hankey GJ, Patel MR, Stevens SR, Becker RC, Breithardt G, Carolei A, Diener HC, Donnan GA, Halperin JL, Mahaffey KW, Mas JL, Massaro A, Norrving B, Nessel CC, Paolini JF, Roine RO, Singer DE, Wong L, Califf RM, Fox KA, Hacke W; ROCKET AF Steering Committee Investigators. Rivaroxaban compared with warfarin in patients with atrial fibrillation and previous stroke or transient ischaemic attack: a subgroup analysis of ROCKET AF. *Lancet Neurol*. 2012;11:315–322. doi: 10.1016/S1474-4422(12)70042-X.
144. Hart RG, Diener HC, Yang S, Connolly SJ, Wallentin L, Reilly PA, Ezekowitz MD, Yusuf S. Intracranial hemorrhage in atrial fibrillation patients during anticoagulation with warfarin or dabigatran: the RE-LY trial. *Stroke*. 2012;43:1511–1517. doi: 10.1161/STROKEAHA.112.650614.
145. Charidimou A, Kakar P, Fox Z, Werring DJ. Cerebral microbleeds and recurrent stroke risk: systematic review and meta-analysis of prospective ischemic stroke and transient ischemic attack cohorts. *Stroke*. 2013;44:995–1001. doi: 10.1161/STROKEAHA.111.000038.
146. Nishikawa T, Ueba T, Kajiwara M, Fujisawa I, Miyamatsu N, Yamashita K. Cerebral microbleeds predict first-ever symptomatic cerebrovascular events. *Clin Neurol Neurosurg*. 2009;111:825–828. doi: 10.1016/j.clineuro.2009.08.011.
147. Bokura H, Saika R, Yamaguchi T, Nagai A, Oguro H, Kobayashi S, Yamaguchi S. Microbleeds are associated with subsequent hemorrhagic and ischemic stroke in healthy elderly individuals. *Stroke*. 2011;42:1867–1871. doi: 10.1161/STROKEAHA.110.601922.
148. Greenberg SM, Eng JA, Ning M, Smith EE, Rosand J. Hemorrhage burden predicts recurrent intracerebral hemorrhage after lobar hemorrhage. *Stroke*. 2004;35:1415–1420. doi: 10.1161/01.STR.0000126807.69758.0e.
149. Soo YO, Yang SR, Lam WW, Wong A, Fan YH, Leung HH, Chan AY, Leung C, Leung TW, Wong LK. Risk vs benefit of anti-thrombotic therapy in ischaemic stroke patients with cerebral microbleeds. *J Neurol*. 2008;255:1679–1686. doi: 10.1007/s00415-008-0967-7.
150. Biffi A, Halpin A, Towfighi A, Gilson A, Busl K, Rost N, Smith EE, Greenberg MS, Rosand J, Viswanathan A. Aspirin and recurrent intracerebral hemorrhage in cerebral amyloid angiopathy. *Neurology*. 2010;75:693–698. doi: 10.1212/WNL.0b013e3181eee40f.
151. Bailey RD, Hart RG, Benavente O, Pearce LA. Recurrent brain hemorrhage is more frequent than ischemic stroke after intracranial hemorrhage. *Neurology*. 2001;56:773–777.
152. van Etten ES, Auriel E, Haley KE, Ayres AM, Vashkevich A, Schwab KM, Rosand J, Viswanathan A, Greenberg SM, Gurol ME. Incidence of symptomatic hemorrhage in patients with lobar microbleeds. *Stroke*. 2014;45:2280–2285. doi: 10.1161/STROKEAHA.114.005151.
153. Eckman MH, Wong LK, Soo YO, Lam W, Yang SR, Greenberg SM, Rosand J. Patient-specific decision-making for warfarin therapy in nonvalvular atrial fibrillation: how will screening with genetics and imaging help? *Stroke*. 2008;39:3308–3315. doi: 10.1161/STROKEAHA.108.523159.
154. Nishikawa T, Ueba T, Kajiwara M, Miyamatsu N, Yamashita K. Cerebral microbleeds in patients with intracerebral hemorrhage are associated with previous cerebrovascular diseases and white matter hyperintensity, but not with regular use of antiplatelet agents. *Neurol Med Chir (Tokyo)*. 2009;49:333–338.
155. Song TJ, Kim J, Lee HS, Nam CM, Nam HS, Heo JH, Kim YD. The frequency of cerebral microbleeds increases with CHADS(2) scores in stroke patients with non-valvular atrial fibrillation. *Eur J Neurol*. 2013;20:502–508. doi: 10.1111/ene.12003.
156. Eckman MH, Singer DE, Rosand J, Greenberg SM. Moving the tipping point: the decision to anticoagulate patients with atrial fibrillation. *Circ Cardiovasc Qual Outcomes*. 2011;4:14–21. doi: 10.1161/CIRCOUTCOMES.110.958108.
157. Antithrombotic Trialists Collaboration. Collaborative meta-analysis of randomised trials of antiplatelet therapy for prevention of death, myocardial infarction, and stroke in high risk patients [published correction appears in *BMJ*. 2002;324:141]. *BMJ*. 2002;324:71–86.
158. Amarenco P, Bogousslavsky J, Callahan A 3rd, Goldstein LB, Hennerici M, Rudolph AE, Sillesen H, Simunovic L, Szarek M, Welch KM, Zivin JA; Stroke Prevention by Aggressive Reduction in Cholesterol Levels (SPARCL) Investigators. High-dose atorvastatin after stroke or transient ischemic attack. *N Engl J Med*. 2006;355:549–559. doi: 10.1056/NEJMoa061894.
159. Hackam DG, Woodward M, Newby LK, Bhatt DL, Shao M, Smith EE, Donner A, Mamdani M, Douketis JD, Arima H, Chalmers J, MacMahon S, Tirschwell DL, Psaty BM, Bushnell CD, Aguilar MI, Capampangan DJ, Werring DJ, De Rango P, Viswanathan A, Danchin N, Cheng CL, Yang YH, Verdel BM, Lai MS, Kennedy J, Uchiyama S, Yamaguchi T, Ikeda Y, Mrkobrada M. Statins and intracerebral hemorrhage: collaborative systematic review and

meta-analysis. *Circulation*. 2011;124:2233–2242. doi: 10.1161/CIRCULATIONAHA.111.055269.

160. Akoudad S, Portegies ML, Koudstaal PJ, Hofman A, van der Lugt A, Ikram MA, Vernooij MW. Cerebral microbleeds are associated with an increased risk of stroke: the Rotterdam Study. *Circulation*. 2015;132:509–516. doi: 10.1161/CIRCULATIONAHA.115.016261.
161. Reddy VY, Sievert H, Halperin J, Doshi SK, Buchbinder M, Neuzil P, Huber K, Whisenant B, Kar S, Swarup V, Gordon N, Holmes D; PROTECT AF Steering Committee and Investigators. Percutaneous left atrial appendage closure vs warfarin for atrial fibrillation: a randomized clinical trial [published correction appears in *JAMA*. 2015;313:1061]. *JAMA*. 2014;312:1988–1998. doi: 10.1001/jama.2014.15192.
162. Demaerschalk BM, Kleindorfer DO, Adeoye OM, Demchuk AM, Fugate JE, Grotta JC, Khalessi AA, Levy EI, Palesch YY, Prabhakaran S, Saposnik G, Saver JL, Smith EE; on behalf of the American Heart Association Stroke Council and Council on Epidemiology and Prevention. Scientific rationale for the inclusion and exclusion criteria for intravenous alteplase in acute ischemic stroke: a statement for healthcare professionals from the American Heart Association/American Stroke Association. *Stroke*. 2016;47:581–641. doi: 10.1161/STR.0000000000000086.
163. Charidimou A, Shoamanesh A, Wilson D, Gang Q, Fox Z, Jäger HR, Benavente OR, Werring DJ. Cerebral microbleeds and postthrombolysis intracerebral hemorrhage risk: updated meta-analysis. *Neurology*. 2015;85:927–934. doi: 10.1212/WNL.0000000000001923.
164. Kakuda W, Thijs VN, Lansberg MG, Bammer R, Wechsler L, Kemp S, Moseley ME, Marks MP, Albers GW; DEFUSE Investigators. Clinical importance of microbleeds in patients receiving IV thrombolysis. *Neurology*. 2005;65:1175–1178. doi: 10.1212/01.wnl.0000180519.27680.0f.
165. Derex L, Nighoghossian N, Hermier M, Adeleine P, Philippeau F, Honnorat J, Yilmaz H, Dardel P, Froment JC, Trouillas P. Thrombolysis for ischemic stroke in patients with old microbleeds on pretreatment MRI. *Cerebrovasc Dis*. 2004;17:238–241. doi: 10.1159/000076123.
166. Kim HS, Lee DH, Ryu CW, Lee JH, Choi CG, Kim SJ, Suh DC. Multiple cerebral microbleeds in hyperacute ischemic stroke: impact on prevalence and severity of early hemorrhagic transformation after thrombolytic treatment. *AJR Am J Roentgenol*. 2006;186:1443–1449. doi: 10.2214/AJR.04.1933.
167. Gratz PP, El-Koussy M, Hsieh K, von Arx S, Mono ML, Heldner MR, Fischer U, Mattle HP, Zubler C, Schroth G, Gralla J, Arnold M, Jung S. Preexisting cerebral microbleeds on susceptibility-weighted magnetic resonance imaging and post-thrombolysis bleeding risk in 392 patients. *Stroke*. 2014;45:1684–1688. doi: 10.1161/STROKEAHA.114.004796.
168. Yan S, Jin X, Zhang X, Zhang S, Liebeskind DS, Lou M. Extensive cerebral microbleeds predict parenchymal haemorrhage and poor outcome after intravenous thrombolysis. *J Neurol Neurosurg Psychiatry*. 2015;86:1267–1272. doi: 10.1136/jnnp-2014-309857.
169. Dannenberg S, Scheitz JF, Rozanski M, Erdur H, Brunecker P, Werring DJ, Fiebach JB, Nolte CH. Number of cerebral microbleeds and risk of intracerebral hemorrhage after intravenous thrombolysis. *Stroke*. 2014;45:2900–2905. doi: 10.1161/STROKEAHA.114.006448.
170. Moriya Y, Takahashi W, Kijima C, Yutani S, Iijima E, Mizuma A, Honma K, Uesugi T, Ohnuki Y, Nagata E, Yanagimachi N, Takizawa S. Predictors for hemorrhagic transformation with intravenous tissue plasminogen activator in acute ischemic stroke. *Tokai J Exp Clin Med*. 2013;38:24–27.
171. Kimura K, Aoki J, Shibazaki K, Saji N, Uemura J, Sakamoto Y. New appearance of extraischemic microbleeds on T2*-weighted magnetic resonance imaging 24 hours after tissue-type plasminogen activator administration. *Stroke*. 2013;44:2776–2781. doi: 10.1161/STROKEAHA.113.001778.
172. Fiehler J, Albers GW, Boulanger JM, Derex L, Gass A, Hjort N, Kim JS, Liebeskind DS, Neumann-Haefelin T, Pedraza S, Rother J, Rothwell P, Rovira A, Schellinger PD, Trenkler J; MR STROKE Group. Bleeding Risk Analysis in Stroke Imaging Before ThromboLysis (BRASIL): pooled analysis of T2*-weighted magnetic resonance imaging data from 570 patients. *Stroke*. 2007;38:2738–2744. doi: 10.1161/STROKEAHA.106.480848.
173. Kidwell CS, Saver JL, Villablanca JP, Duckwiler G, Fredieu A, Gough K, Leary MC, Starkman S, Gobin YP, Jahan R, Vespa P, Liebeskind DS, Alger JR, Vinuela F. Magnetic resonance imaging detection of microbleeds before thrombolysis: an emerging application. *Stroke*. 2002;33:95–98.
174. Turc G, Sallem A, Moulin S, Tisserand M, Machet A, Edjlali M, Baron JC, Leclerc X, Leys D, Mas JL, Cordonnier C, Oppenheim C. Microbleed status and 3-month outcome after intravenous thrombolysis in 717 patients with acute ischemic stroke. *Stroke*. 2015;46:2458–2463. doi: 10.1161/STROKEAHA.115.009290.
175. Akins PT, Amar AP, Pakbaz RS, Fields JD; SWIFT Investigators. Complications of endovascular treatment for acute stroke in the SWIFT trial with Solitaire and Merci devices. *AJNR Am J Neuroradiol*. 2014;35:524–528. doi: 10.3174/ajnr.A3707.
176. Shi ZS, Duckwiler GR, Jahan R, Tateshima S, Gonzalez NR, Szeder V, Saver JL, Kim D, Ali LK, Starkman S, Vespa PM, Salamon N, Villablanca JP, Viñuela F, Feng L, Loh Y, Liebeskind DS. Mechanical thrombectomy for acute ischemic stroke with cerebral microbleeds. *J Neurointerv Surg*. 2016;8:563–567. doi: 10.1136/neurintsurg-2015-011765.
177. Diedler J, Ahmed N, Sykora M, Uyttenboogaart M, Overgaard K, Luijckx GJ, Soinne L, Ford GA, Lees KR, Wahlgren N, Ringleb P. Safety of intravenous thrombolysis for acute ischemic stroke in patients receiving antiplatelet therapy at stroke onset. *Stroke*. 2010;41:288–294. doi: 10.1161/STROKEAHA.109.559724.
178. DeBaun MR, Gordon M, McKinstry RC, Noetzel MJ, White DA, Sarnaik SA, Meier ER, Howard TH, Majumdar S, Inusa BP, Telfer PT, Kirby-Allen M, McCavit TL, Kamdem A, Airewele G, Woods GM, Berman B, Panepinto JA, Fuh BR, Kwiatkowski JL, King AA, Fixler JM, Rhodes MM, Thompson AA, Heiny ME, Redding-Lallinger RC, Kirkham FJ, Dixon N, Gonzalez CE, Kalinyak KA, Quinn CT, Strouse JJ, Miller JP, Lehmann H, Kraut MA, Ball WS Jr, Hirtz D, Casella JF. Controlled trial of transfusions for silent cerebral infarcts in sickle cell anemia. *N Engl J Med*. 2014;371:699–710. doi: 10.1056/NEJMoa1401731.
179. DeBaun MR. The challenge of creating an evidence-based guideline for sickle cell disease. *JAMA*. 2014;312:1004–1005. doi: 10.1001/jama.2014.11103.
180. Yawn BP, Buchanan GR, Afenyi-Annan AN, Ballas SK, Hassell KL, James AH, Jordan L, Lanzkron SM, Lottenberg R, Savage WJ, Tanabe PJ, Ware RE, Murad MH, Goldsmith JC, Ortiz E, Fulwood R, Horton A, John-Sowah J. Management of sickle cell disease: summary of the 2014 evidence-based report by expert panel members [published corrections appear in *JAMA*. 2014;312:1932 and *JAMA*. 2015;313:729]. *JAMA*. 2014;312:1033–1048. doi: 10.1001/jama.2014.10517.
181. Callaghan BC, Kerber KA, Pace RJ, Skolarus LE, Burke JF. Headaches and neuroimaging: high utilization and costs despite guidelines. *JAMA Intern Med*. 2014;174:819–821. doi: 10.1001/jamainternmed.2014.173.
182. Wang Z, Soo YO, Mok VC. Cerebral microbleeds: is antithrombotic therapy safe to administer? *Stroke*. 2014;45:2811–2817. doi: 10.1161/STROKEAHA.114.004286.
183. Whiteley WN, Thompson D, Murray G, Cohen G, Lindley RI, Wardlaw J, Sandercock P; IST-3 Collaborative Group. Targeting recombinant tissue-type plasminogen activator in acute ischemic stroke based on risk of intracranial hemorrhage or poor functional outcome: an analysis of the Third International Stroke Trial. *Stroke*. 2014;45:1000–1006. doi: 10.1161/STROKEAHA.113.004362.
184. Sprint Research Group, Wright JT Jr, Williamson JD, Whelton PK, Snyder JK, Sink KM, Rocco MV, Reboussin DM, Rahman M, Oparil S, Lewis CE, Kimmel PL, Johnson KC, Goff DC Jr, Fine LJ, Cutler JA, Cushman WC, Cheung AK, Ambrosius WT. A randomized trial of intensive versus standard blood-pressure control. *N Engl J Med*. 2015;373:2103–2116.