

3RD DAILY CARDIOLOGY SYMPOSIUM

CONCISE, PRECISE, PRACTICAL

1st Day, 1st Panel, 2nd Lecture

Acute Arrhythmia

**Approach to diagnosis and management of
narrow-complex tachyarrhythmias**



Learning Objectives & Case Vignette

Learning Objectives

- Differential diagnoses of narrow QRS tachycardia
- Clinical manifestations of narrow complex tachycardia
- Evaluation and approach to the patients with narrow QRS tachycardia
- The acute management of different types of narrow QRS tachycardia
- Discharge criteria, long term follow up & referral of narrow QRS tachycardia

Case Vignette

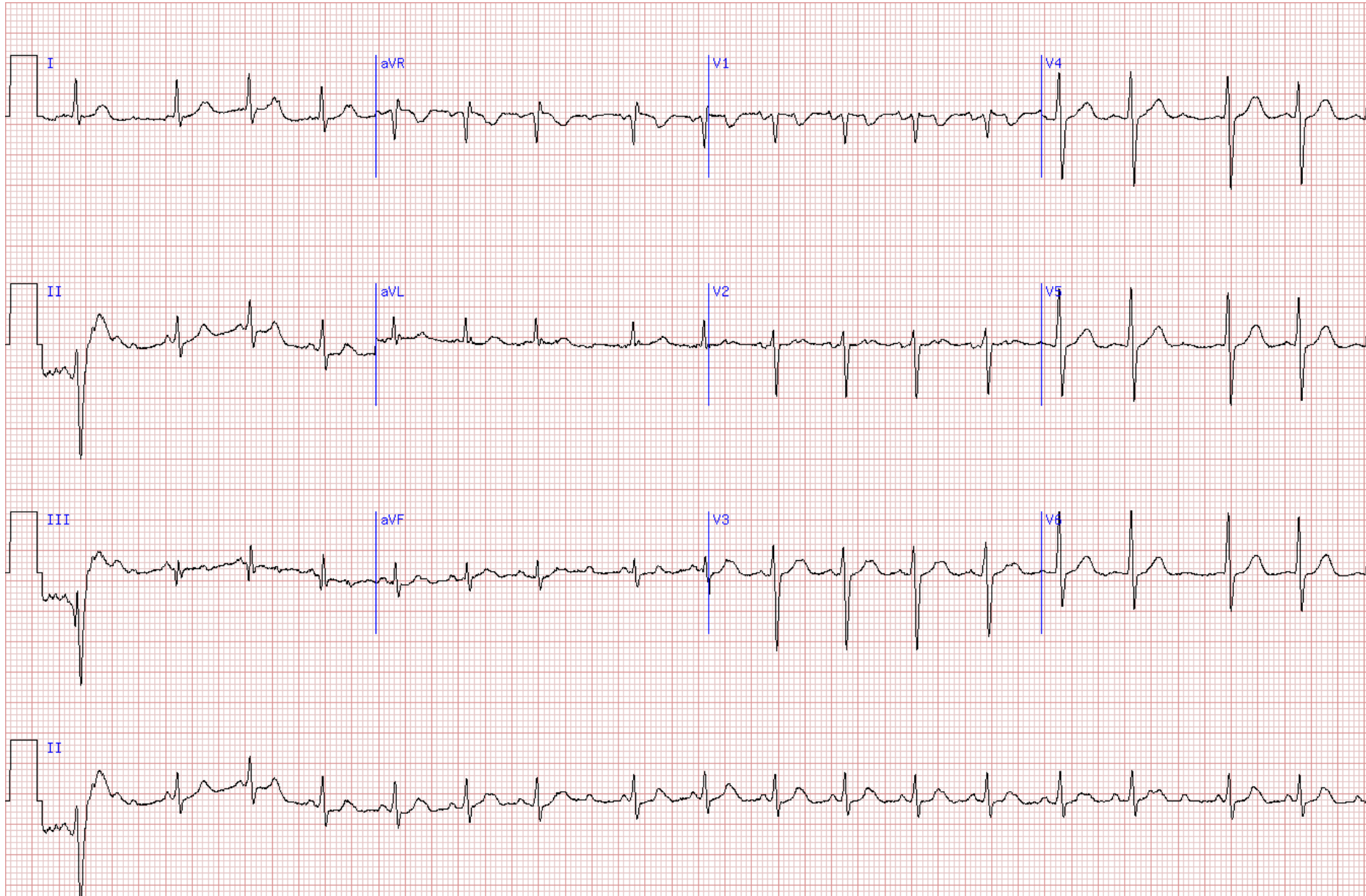
- 65 Y/O gentleman with Hx. of T2D, HTN and IHD
- S/P PCI on LAD in ACS setting 3 yrs ago, EF: 45%
- Under Tx by:
 - Aspirin 80mg OD
 - Atorvastatin 40mg OD
 - Empagliflozin/Metformin 12.5/1000mg BID
 - Pantoprazole 40mg OD
 - Bisoprolol 2.5mg OD
 - Lisinopril 5mg OD

Case Vignette con.

- The patient reports having palpitations for the past few days
- Came to ED with deterioration of palpitation and anxiety
- He's alert, he's not in respiratory distress and he reports no chest pain
- Ph/E:
 - Lungs Clear
 - SBP: 110 mmHg
 - HR: 125 bpm

**What is your interpretation of the ECG (next page)
and what are the next steps?**

ECG



**Stay Tuned with
Daily Cardiology Symposium 1402**

Acute arrhythmia

Tir 22nd, 11:30 – 13:00

**Approach to diagnosis and management of
narrow-complex tachyarrhythmia**

M. Haghjoo, MD



DailyCardiology.com